



JUVENILE NASOPHARYNGEAL ANGIOFIBROMA SURGERY

Derek Rogers, Christopher Hartnick, Johan Fagan

Juvenile nasopharyngeal angiofibroma (JNA) is a rare tumour representing only about 0.05% of head and neck tumours.¹ The most common presentation is a prepubescent or adolescent male with severe, recurrent epistaxis and nasal obstruction. The epistaxis may even require a blood transfusion. Since JNAs occur exclusively in males, a hormonal theory has been implicated.

As these tumours are quite rare, many patients may have been treated conservatively by a primary care provider before being referred to an otolaryngologist. Patients may have undergone a trial of nasal steroids and antihistamines or been mistaken for having simple anterior epistaxis. An adolescent male with recurrent epistaxis and chronic nasal obstruction is highly suspicious for a JNA. The epistaxis and nasal obstruction progressively worsen. Unilateral nasal obstruction may progress to bilateral obstruction as the tumour grows to fill the nasopharynx. Other common symptoms include headache, facial swelling, unilateral rhinorrhoea, hyposmia, and ipsilateral conductive hearing loss due to Eustachian tube dysfunction.

JNAs originate from the sphenopalatine artery near the sphenopalatine foramen, an anatomic area usually readily accessible via endoscopic technique. Hence most of these tumours are now removed via an endoscopic approach by surgeons skilled in endoscopic surgery working in properly equipped centres. Compared to open approaches, the endoscopic approach results in less intraoperative blood loss, fewer complications, lower rates of recurrence, and shorter hospital stays.² Due to the vascularity of these tumours, preoperative embolization of major feeding vessels by interventional radiology leads to signifi-

cantly less blood loss and facilitates endoscopic resection.³

Traditionally, several open approaches are employed, including lateral rhinotomy, midfacial degloving, transmaxillary (Caldwell-Luc), transpalatal, Le Fort 1 and infratemporal fossa approaches. Extensive tumours, such as those with lateral infratemporal fossa involvement or significant optic canal or intracranial extension may necessitate an open or a combined open and endoscopic approach. Radiotherapy and anti-androgen therapy are reserved for tumours deemed inoperable.⁴

Pertinent Anatomy

It is essential that a surgeon be familiar with the detailed vascular anatomy of the maxillary artery and its terminal branches, and that of the maxilla, paranasal sinuses, pterygoplatine fossa, orbit and anterior skull base. Studying a cadaver skull and having it available in the operating room is of great value.

Vascular anatomy

JNAs typically arise from the sphenopalatine artery, which is a terminal branch of the internal maxillary artery. The internal maxillary artery branches off the external carotid artery (*Figures 1, 2*). The sphenopalatine artery usually contains two or more branches. Larger tumours can however have arterial supply from the ascending pharyngeal, contralateral internal maxillary artery, and be supplied by the cavernous portion of the internal carotid artery at the lateral wall of sphenoid sinus.

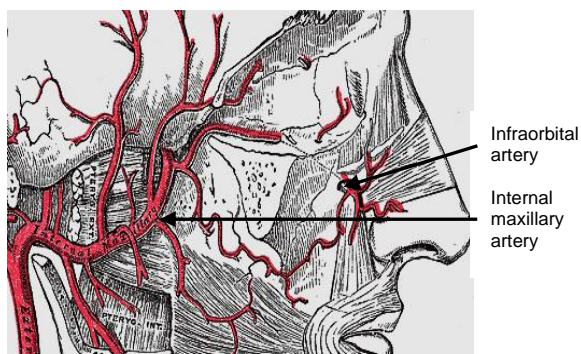

Figure 1: Internal maxillary artery entering pterygopalatine fossa through pterygomaxillary fissure (mandible removed)

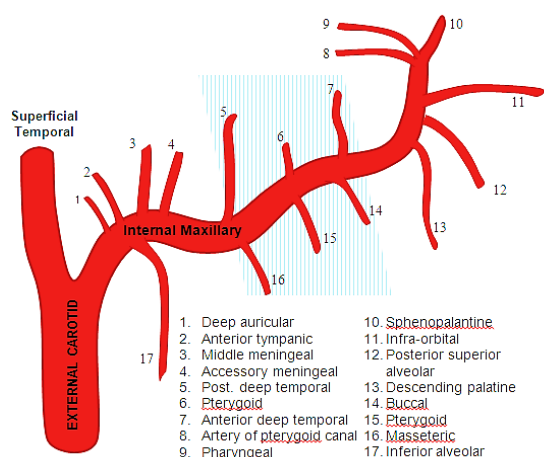


Figure 2: Branches of internal maxillary artery; blue shading denotes 2nd part of internal maxillary artery before it enters pterygopalatine fossa

Bony anatomy (Figures 3, 4)

JNAs typically arise from the lateral nasal wall at the sphenopalatine foramen and generally involve the pterygopalatine fossa. The **sphenopalatine foramen** is located along the lateral nasal wall immediately posterior to the *crista ethmoidalis* and opens into the middle and superior meati (Figures 3-5). The **pterygopalatine fossa** is located immediately behind the thin posterior wall of the maxillary sinus (Figures 3, 4). It serves as a gateway to the nasal and oral cavities, infratemporal fossa, orbit, pharynx, and middle cranial fossa through

eight foramina.⁵ It communicates laterally with the infratemporal fossa via the pterygomaxillary fissure, and medially with the nasal cavity via the sphenopalatine foramen (Figures 3, 4). Immediately posterior are the pterygoid plates (Figures 3-9). Figures 7 & 8 show axial views of the anatomy of the pterygopalatine fossa, pterygomaxillary fissure, and maxillary sinus.

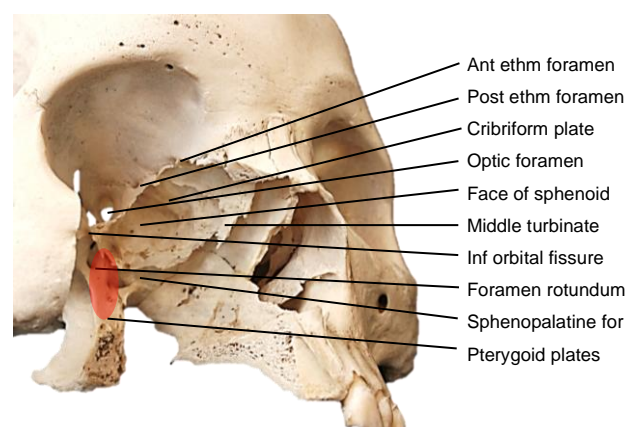


Figure 3: Total maxillectomy defect illustrating the relations of the pterygopalatine fossa (Red)

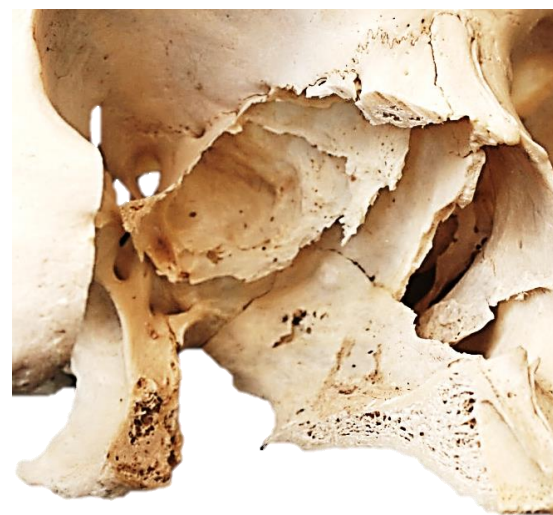

Figure 4: Close-up of Figure 3

Figures 3, 4 & 9 demonstrate the coronal anatomy immediately posterior to the maxillary sinus in which the internal maxillary artery and its branches as well as the sphenopalatine ganglion and its branches are encountered within the pterygopala-

tine fossa. It also illustrates how a JNA may extend superiorly through the inferior orbital fissure into the orbit, medially into the nasal cavity and sphenoid, and laterally into the infratemporal fossa.

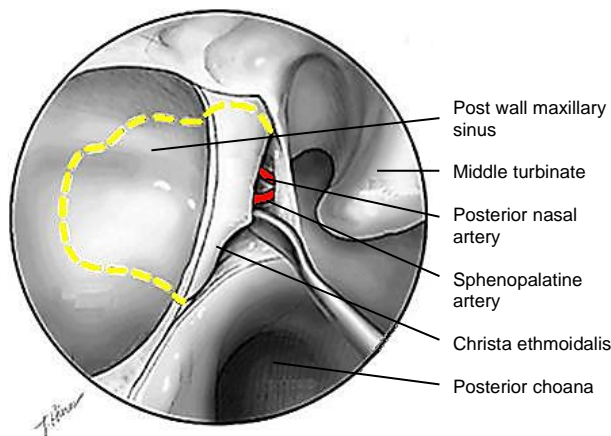


Figure 5: Endoscopic view of posterior wall of (R) maxillary antrum through a large middle meatal antrostomy: sphenopalatine artery is located directly posterior to crista ethmoidalis; posterior nasal artery is superior to sphenopalatine artery (Adapted from Statham MM, Tami TA. Endoscopic anatomy of the pterygopalatine fossa. Oper Tech Otolaryngol.2006;17(3):197-200.)

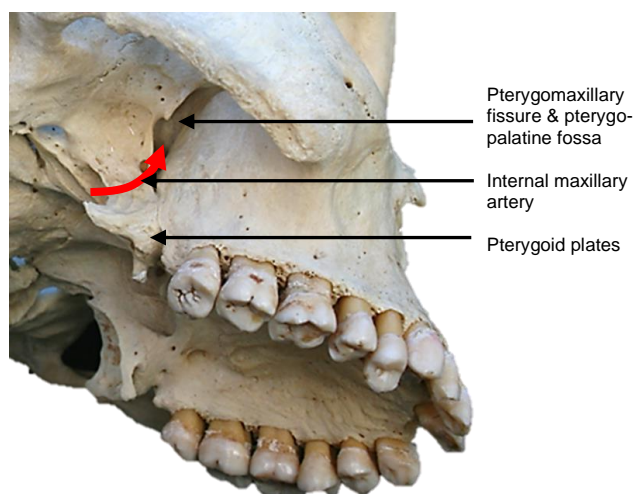


Figure 6: Internal maxillary artery (red arrow) traverses the pterygomaxillary fissure to enter the pterygopalatine fossa

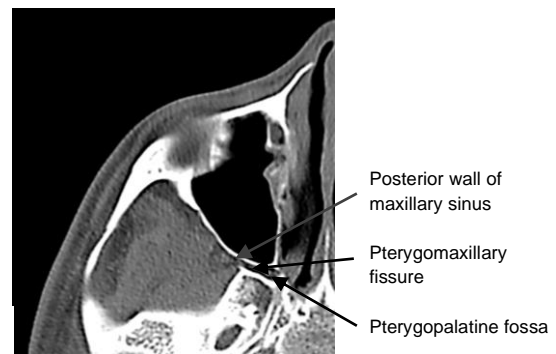


Figure 7: Axial cut at level of infraorbital nerve and orbital floor

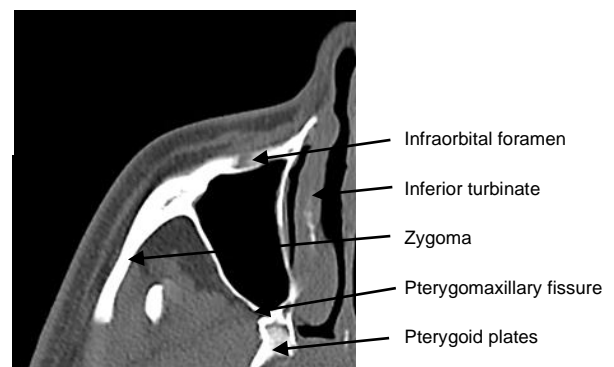


Figure 8: Axial cut at level of infraorbital foramen and pterygoid plates

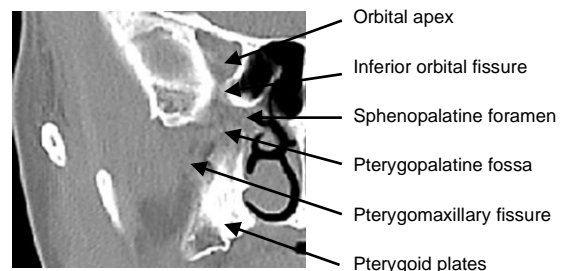


Figure 9: Coronal cut immediately behind the maxillary sinus through the orbital apex, pterygoid plates and pterygopalatine fossa

Nerves

The **maxillary division of trigeminal (V2)** enters the pterygopalatine fossa via foramen rotundum (Figures 7, 10). The **infraorbital nerve** is a terminal branch of V2 and runs in the floor of the orbit/roof of the antrum to exit the infraorbital foramen.

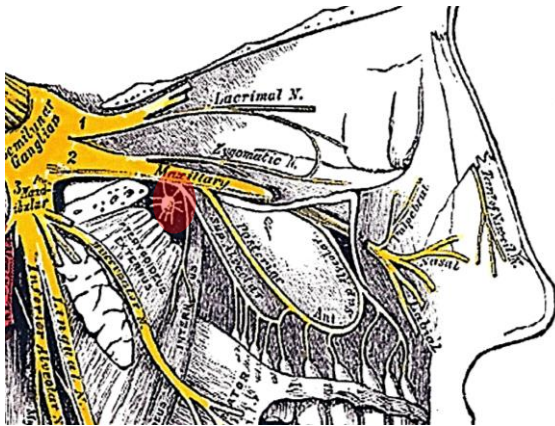


Figure 10: V2, pterygopalatine ganglion and infraorbital nerve (pterygopalatine fossa in red)

Preoperative Evaluation

Clinical Evaluation

A thorough history and physical are performed. The history should focus on the aforementioned nasal symptoms as well as any orbital symptoms. The initial head and neck physical examination notes any proptosis, vision changes, facial swelling, or otitis media with effusion. Fiberoptic nasopharyngoscopy is performed which typically reveals a vascular mass emanating from the posterior aspect of the middle and/or superior meatus, possibly filling the nasopharynx (Figure 11). **The mass must not be biopsied** due to the risk of causing significant epistaxis and as it may represent an encephalocele or other nasal mass with an intracranial component.

Radiologic Evaluation

CT and MRI scans with contrast should be obtained to evaluate the extent of the tumour. CT scan helps delineate the bony anatomy (Figures 12a, b). JNAs usually cause widening of the sphenopalatine foramen and may cause anterior bowing of the posterior wall of the maxillary sinus, also known as the Holman-Miller sign (Figure 12b).

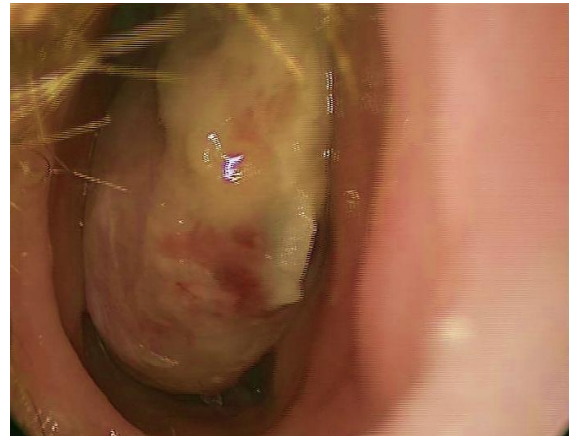

Figure 11: View of right nasal cavity showing large, vascular mass

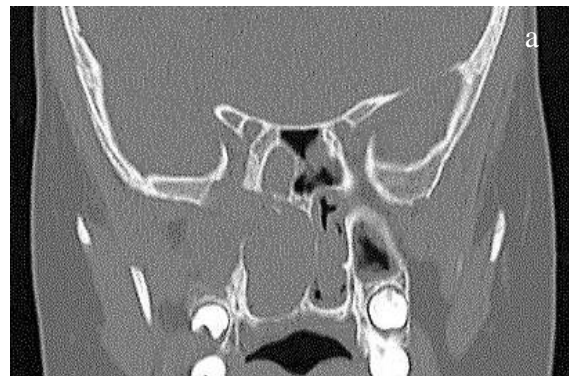

Figure 12a: CT scan: Widening of the sphenopalatine foramen and nasal cavity

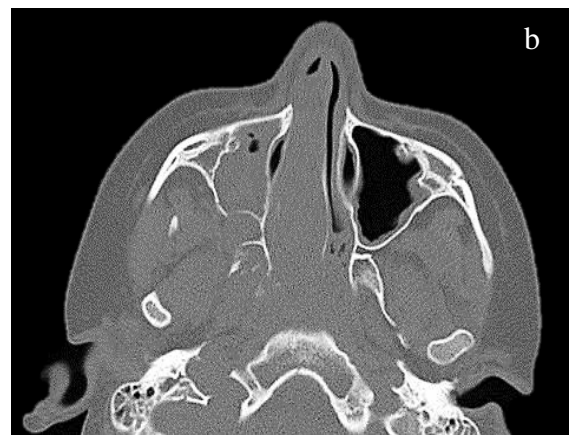

Figure 12b: CT scan: Anterior bowing of posterior wall of maxillary sinus (Holman-Miller sign) and nasal mass

MRI provides essential information regarding soft tissue structures including the tumour, orbital structures, and intracranial components (Figures 13a, b). It also per-

mits a distinction to be made between retained sinus secretions and mucosal oedema vs. tumour.

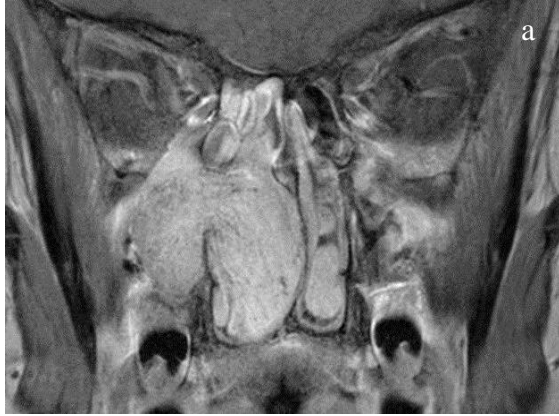


Figure 13a: MRI: No orbital or intracranial extension

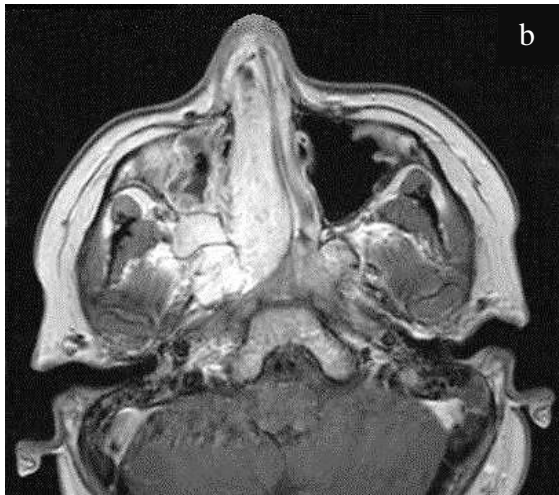

Figure 13b: MRI: Extension to medial infratemporal fossa

Staging systems

Several staging systems have been proposed based on the radiologic appearance of JNAs. Two commonly used systems were developed by Fisch ⁶ (Table 1) and Radkowski ⁷ (Table 2). More recently a staging system was proposed based primarily on prognostic factors for endoscopic resection (Table 3). ⁸

Table 1: Fisch Staging for JNA

Stage	Description of Tumour Involvement
I	Limited to nasopharynx, bone destruction negligible or limited to sphenopalatine foramen
II	Invades pterygopalatine fossa or maxillary, ethmoid, or sphenoid sinus with bone destruction
III	Invades infratemporal fossa or orbital region IIIA: No intracranial involvement IIIB: Extradural, parasellar involvement
IV	Invades dura IVA: Without cavernous sinus, pituitary, or optic chiasm involvement IVB: With the above

Table 2: Radkowski Staging for JNA

Stage	Description of Tumour Involvement
I	IA: Limited to nose or nasopharynx IB: Same as above but involving ≥ 1 sinus
II	IIA: Minimal extension through sphenopalatine foramen and into medial pterygomaxillary fossa IIB: Full occupation of pterygomaxillary fossa displacing posterior wall of maxillary sinus forward, orbit erosion, displacement of maxillary artery branches IIC: Involvement of infratemporal fossa or cheek, or posterior to pterygoid plates
III	Erosion of skull base IIIA: Minimal intracranial involvement IIIB: Extensive intracranial involvement or any cavernous sinus extension

Table 3: University of Pittsburgh Medical Center (UPMC) Staging for JNA

Stage	Description of Tumour Involvement
I	Nasal cavity, medial pterygopalatine fossa
II	Paranasal sinuses, lateral pterygopalatine fossa, no residual vascularity
III	Skull base erosion, orbit, infratemporal fossa, no residual vascularity
IV	Skull base erosion, orbit, infratemporal fossa, with residual vascularity
V	Intracranial extension, residual vascularity Medial (M): Medial cavernous sinus Lateral (L): Middle cranial fossa

Angiography

Angiography is both diagnostic and therapeutic; it is performed 24-72 hours before surgery to determine the precise blood supply to the tumour and to embolise feeding vessels. Flooding the tumour with small particles is preferred, as coiling major vessels proximally precludes subsequent embolisation should the tumour recur. By thrombosing the tumour with microparticles, smaller supply vessels from *e.g.* the internal carotid artery system also thrombose; hence bleeding from the internal carotid artery generally does not present a problem when delivering tumour from the sphenoid sinus. It is important that the surgeon discusses the outcome of the embolisation with the interventional radiologist to determine how successful the embolisation had been, and what vessels need to be surgically ligated or clipped (*Figures 14a, b*).

Should interventional angiography not be available, then surgery must be planned in such a way as to gain proximal vascular control of the internal maxillary artery and/or external carotid artery prior to attempting resection.

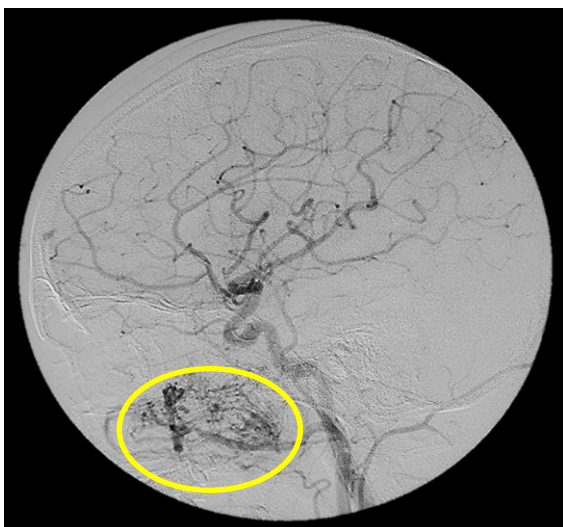


Figure 14a: JNA (circled) supplied by internal maxillary and ascending pharyngeal arteries

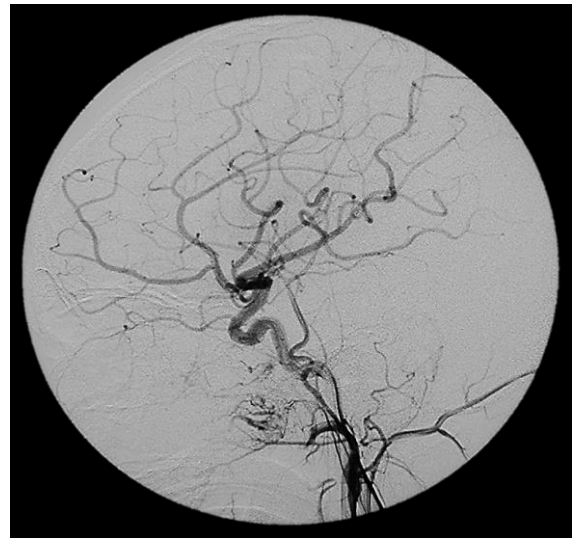

Figure 14b: JNA following embolization with persistent supply from ascending pharyngeal artery

General surgical principles

- JNAs may be resected by endoscopic, open or combined (endoscopic & open) techniques
- The surgical approach is dependent on
 - Tumour location and extent
 - Pattern of vascular supply
 - Effectiveness of embolisation
 - Facial skeletal maturity
 - Experience of the surgical team
- Carefully plan surgical approach(es) according to the imaging studies
- In expert hands and with effective preoperative embolisation, most JNAs can be removed endoscopically with reduced morbidity
- ***Complete all bone work and ensure good access to the tumour before attempting resection, because once bleeding is encountered, the surgery may become very difficult and hazardous, and haemostasis may only be possible after completing the tumour resection***
- In young patients, avoid excessive soft tissue and bone dissection of the mid-face to minimise the risk of causing growth abnormalities⁹

Anaesthesia considerations

- Patients are placed supine in reverse Trendelenburg position
- Oral RAE® endotracheal tube permits unobstructed access to the nose
- Hypotensive general anaesthesia
- Type and crossmatch 2 units of blood as rapid blood loss can occur; consider banking 2 units of autologous blood one week before surgery
- Intraoperative blood salvage (autologous blood transfusion/cell salvage/cell saver technique) can be employed to recover blood lost during surgery which is reinfused into the patient

Endoscopic resection

Indications

- Tumours involving nasal cavity, paranasal sinuses, and nasopharynx
- Tumours with only medial infratemporal fossa involvement or extradural parasellar involvement with limited intracranial extension
- Facilitation of open approaches

Relative contraindications

Lateral infratemporal fossa involvement, extensive parasellar extension, encasement of the optic nerve, intradural spread, or cavernous sinus involvement. Note that cavernous sinus involvement is often overestimated on MRI scan due to hypervascularity of the tumour bed.

Intraoperative considerations

- Self-cleaning endoscope such as Endo-Scrub®
- Suction bipolar electrocautery, suction Freer elevator, suction Blakesley forceps or Kerrison rongeur, and haemoclclip applier

- Intraoperative image guidance (if available)

Procedure

- Inject Lidocaine with epinephrine into the greater palatine foramina, septum, uncinate and middle turbinate on the side with the tumour
- Pack both nasal cavities for 10min with cottonoid pledgets soaked in oxymetazoline
- On the side with the tumour, amputate the inferior aspect of the middle turbinate with scissors (*Figure 15*)

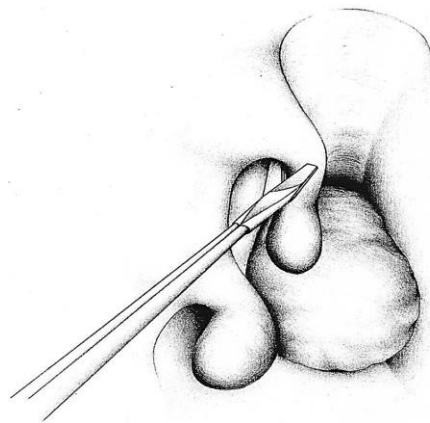


Figure 15: The middle turbinate is amputated to provide access to the tumour (Reprinted with permission from Wormald PJ, Van Hasselt A. Endoscopic removal of juvenile angiofibromas. *Otolaryngol Head Neck Surg.* 2003;129(6):684-91. SAGE Publications)

- The tumour may initially need to be partially debulked to identify landmarks (only if well embolised)
- Perform an uncinctomy and wide middle meatal antrostomy
- Enlarge the middle meatal antrostomy until the posterior wall of the maxillary sinus is clearly visible (*Figures 5, 16*)
- Consider doing a posterior septectomy to allow better visualisation and access from the opposite nasal cavity

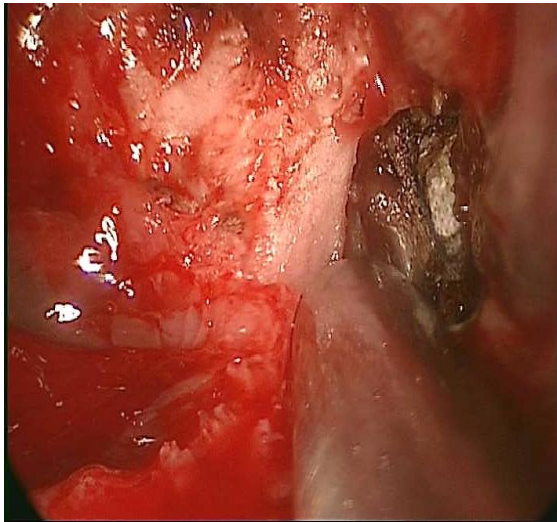


Figure 16: Intraoperative photo (right nose) following middle meatal antrostomy, showing crista ethmoidalis and posterior maxillary sinus wall

- Perform a total ethmoidectomy and identify the sphenoid rostrum
- Completed a sphenoidotomy to ensure that tumour does not extend into the sphenoid
- Expose the sphenopalatine artery and tumour pedicle by removing the posterior wall of the maxillary sinus (*Figures 17-19*)

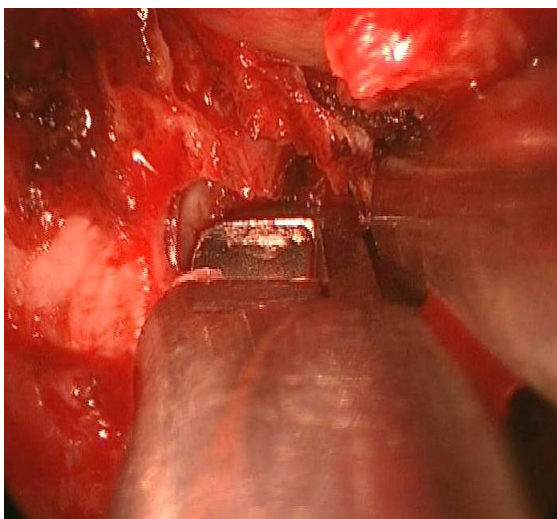


Figure 17: Intraoperative photo showing Kerrison rongeur used to remove posterior maxillary sinus wall

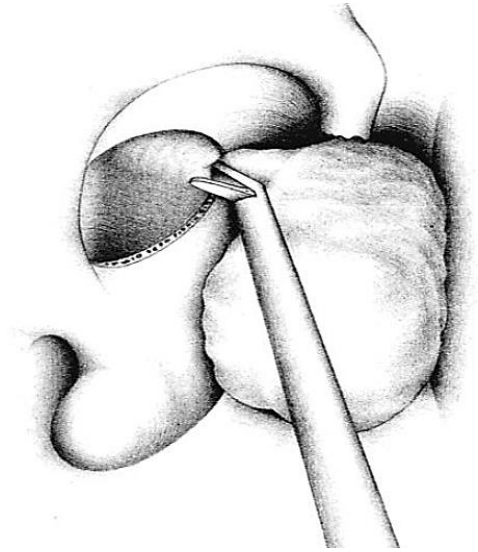


Figure 18: The posterior wall of the maxillary sinus is removed along the sphenopalatine artery (Reprinted with permission from Wormald PJ, Van Hasselt A. Endoscopic removal of juvenile angiofibromas. Otolaryngol Head Neck Surg. 2003;129(6):684-91. SAGE Publications)

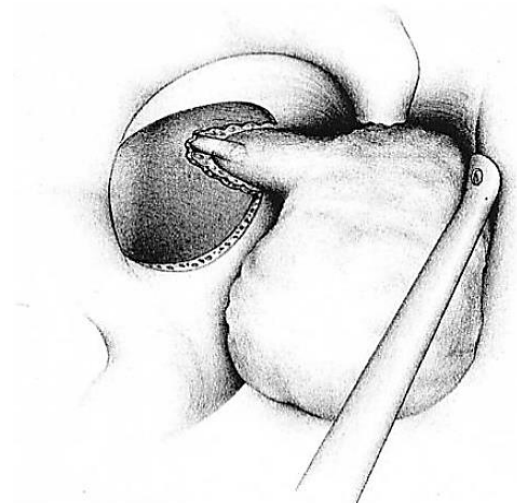


Figure 19: The tumour is dissected to its vascular pedicle (Reprinted with permission, from Wormald PJ, Van Hasselt A. Endoscopic removal of juvenile angiofibromas. Otolaryngol Head Neck Surg. 2003;129(6):684-91. SAGE Publications)

- Isolate and clip/ligate the sphenopalatine artery lateral to the tumour, **even if it has been embolised** (*Figure 20*)
- If tumour extends beyond the limits of the endoscopic instruments *e.g.* beyond the pterygopalatine fossa into the infratemporal fossa, then a Caldwell-Luc approach or open procedure may be needed for access

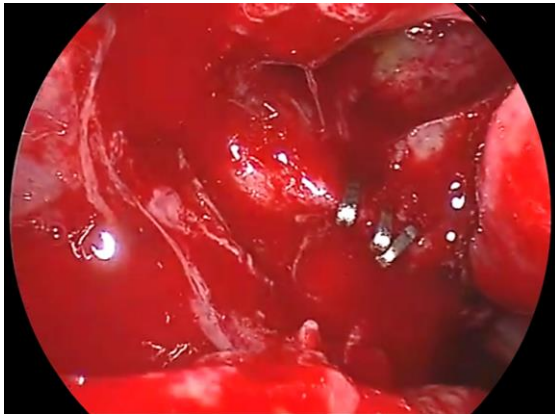


Figure 20: Sphenopalatine artery has been clipped in the pterygopalatine fossa

- Dissect tumour off adjacent structures; often it is adherent to septum, sphenoid rostrum, skull base, and nasopharynx
- Suction bipolar electrocautery is first used to ablate feeding vessels along the surface of the tumour; a suction Freer elevator or knife is used to release adhesions
- The tumour is dissected free until all that remains is the pedicle
- If it has not yet been done, apply haemoclips to branches of sphenopalatine artery, divide the artery, and deliver the tumour via the nasopharynx and out the mouth
- Inspect the entire mucosal area that was involved with tumour
- Biopsies may be sent to clear the margins
- Obtain meticulous haemostasis
- Apply haemostatic sinus material, such as *Arista™* powder, *Stammberger Sinufoam™*, or *Surgicel* to bleeding surfaces

Postoperative Care

- The patient is admitted to the ward for overnight observation
- If intraoperative blood loss was significant, a full blood count is obtained and the patient is transfused if needed
- Oxymetazoline is used for minor epistaxis

- Nasal saline irrigations are started on the 1st postoperative day, at least twice daily, for nasal toilet
- The patient is instructed not to blow the nose
- The 1st postoperative visit is scheduled at 1 week

Complications

- Standard risks of endoscopic sinus surgery apply including pain, bleeding, infection, hyposmia, synechiae, orbital injury, loss of vision, cerebrospinal fluid leak, and intracranial injury
- Bleeding requiring transfusion
- Tumour recidivism if margins are not cleared

Key Points

- Tumour removal and postoperative recovery are greatly facilitated by preoperative embolisation
- Intraoperative navigation may aid the surgeon
- Special endoscopic instruments with suction capacity are helpful to dissect these vascular tumours
- First complete all bone work to gain good access before attempting to resect tumour
- Be prepared to convert to an open approach if tumour involves the lateral infratemporal fossa or parasellar region

Open approaches

Open approaches are employed for tumours that extend to the lateral infratemporal fossa, tumours with intradural extension, and in centres that lack endoscopic expertise. Open approaches may also be used in conjunction with endoscopic resection *e.g.* anterior antrostomy ([Caldwell-Luc](#)) may be employed to gain access to and clip the internal maxillary artery lateral to a large tumour or to access the infra-

temporal fossa. Conversely, the endoscope can be used at the conclusion of an open resection to inspect the tumour bed to ensure complete resection and to obtain haemostasis. Open approaches include the following:

- [Medial maxillectomy](#)
- Le Fort 1 osteotomy
- Transpalatal
- [Maxillary swing](#)
- Infratemporal fossa
- Facial translocation

An approach or combinations of approaches is carefully selected according to the location of the tumour and its extensions (*Table 4*)⁹. Readers are referred to chapters on [Total Maxillectomy](#), [Inferior Maxillectomy](#), [Medial Maxillectomy](#), and [Maxillary Swing approaches](#) for additional detail about these approaches.

	Endosc	Transpal	Le Fort 1	Medial maxillect	ITF	Facial transloc
Nasopharynx						
Intranasal						
Ethmoids						
Sphenoid						
Pt Pal Fossa						
Medial ITF						
Lateral ITF						
Medial cav sinus						
Lateral cav sinus						
Middle cranial fossa						

Table 4: Access provided by different surgical approaches⁹

Medial maxillectomy

[Medial maxillectomy](#) is suited to tumours limited to the nose, nasopharynx, sphenoid, pterygopalatine fossa, medial infratemporal fossa and medial cavernous sinus (*Table 4*). Unless an ethmoidectomy is required, the medial maxillectomy is more limited than that described in the chapter on [medial maxillectomy](#).

- Soft tissue elevation is generally done by midfacial degloving approach (*Figure 21*); lateral rhinotomy is only required when the superior parts of the ethmoids are to be dissected (*Figure 22*)

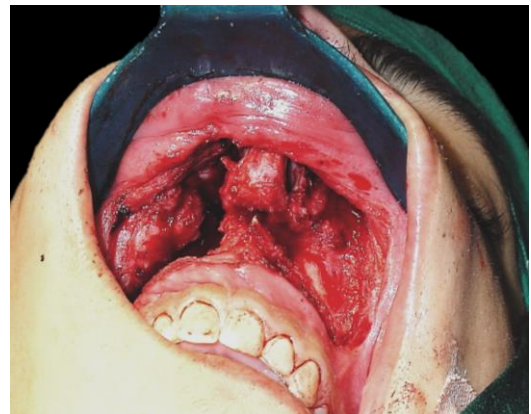

Figure 21: Midfacial degloving approach with right medial maxillectomy

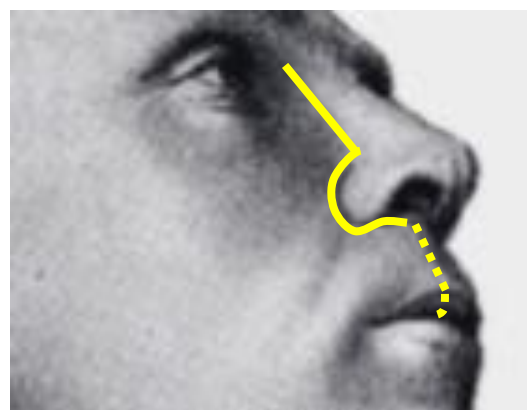


Figure 22: Lateral rhinotomy incision. Very rarely is a lip split extension required for access

- Inspect the antrum to determine the tumour extent and to plan the subsequent bony cuts
- The extent of the subsequent bony resection is tailored to the JNA
- A medial maxillectomy can now be done (*Figure 23*); *Figures 24a-c* illustrate the extent of the bone resection with the limited medial maxillectomy generally required for JNAs

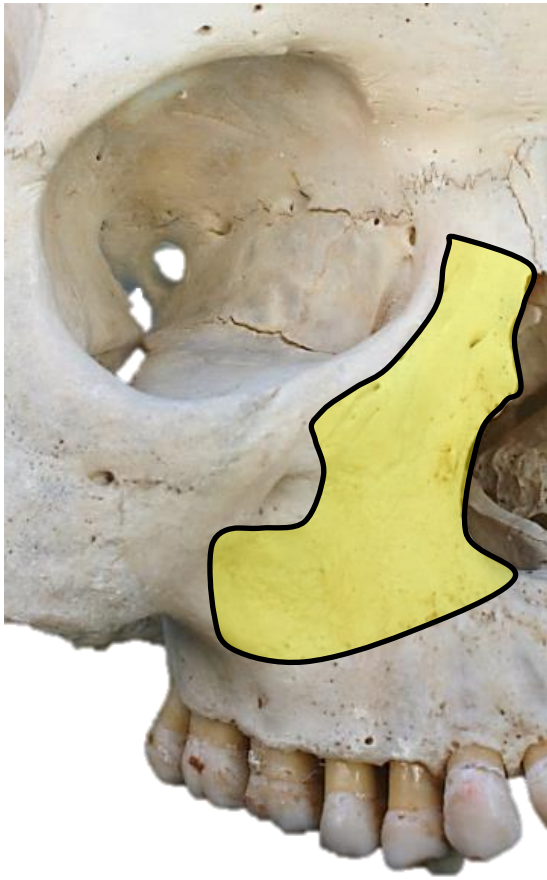

Figure 23: Medial maxillectomy: typical bony removal for access to a JNA

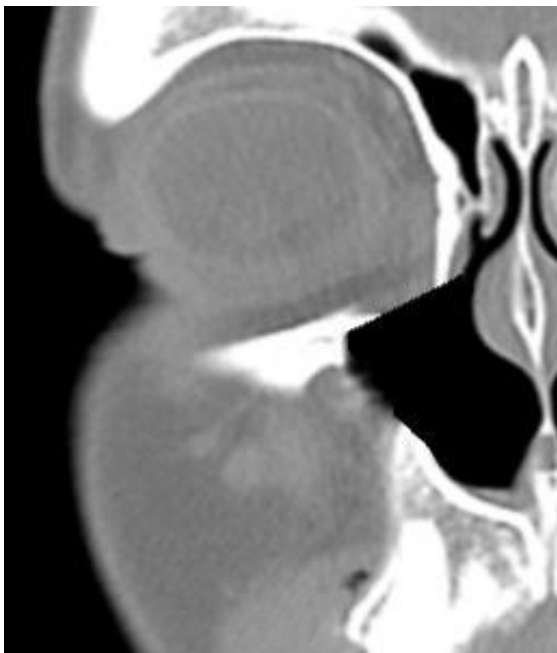

Figure 24a: Anterior coronal CT slice demonstrating resected lateral nasal wall, and transected lacrimal sac

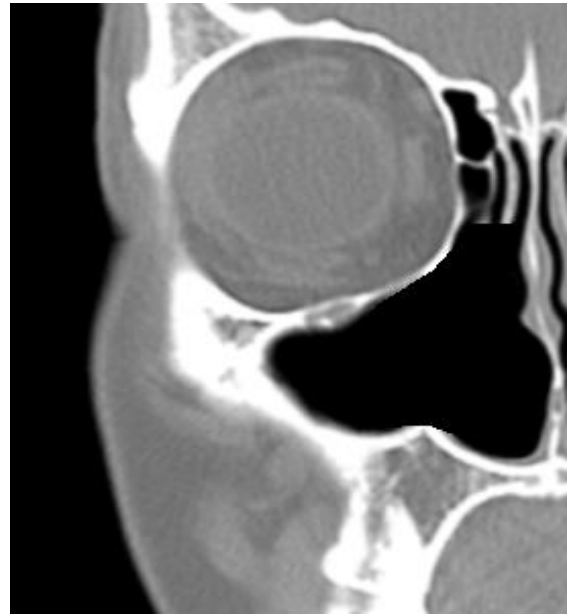

Figure 24b: Coronal CT through mid-antrum demonstrates resected lateral nasal wall including inferior turbinate, uncinate process and trimmed middle turbinate

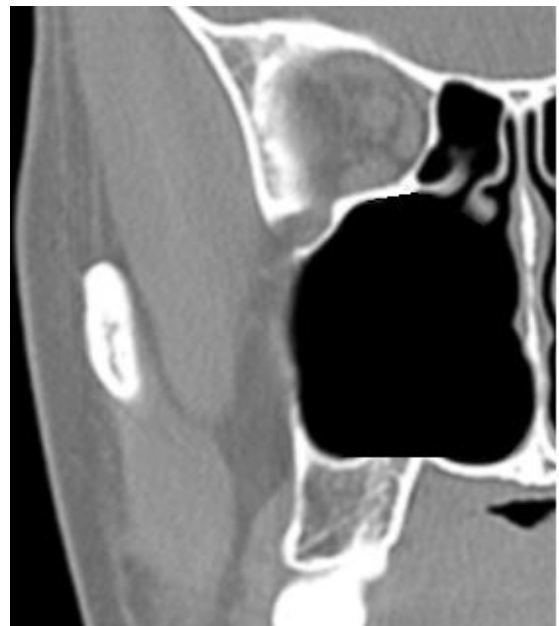


Figure 24c: Coronal CT through posterior antrum demonstrating resected lateral nasal wall and inferior turbinate

- *The sequence of the osteotomies is planned to reserve troublesome bleeding to the end*
 1. ***Osteotomy below inferior orbital rim:*** A sharp osteotome/power saw/

bone nibbler is used to cut along the thick inferior orbital rim just medial to the infraorbital nerve (Figures 23, 24)

2. **Osteotomy connecting antrostomy with nasal vestibule:** A sharp osteotome is used to connect the anterior antrostomy with the floor of the nasal vestibule (Figures 23, 24)
3. **Osteotomy across frontal process of maxilla:** This part of the dissection is often best done with a Kerri-son's rongeur or oscillating saw. There is often persistent minor bleeding from the bone that may be controlled with bone wax or cautery (Figure 23)
4. **Osteotomy along floor of nose:** A sharp osteotome or heavy scissors is used to divide the lateral wall of the nose/medial wall of the antrum along the floor of the nasal cavity up to the posterior wall of the antrum. When doing this dissection with an osteotome, the dissection is halted when the osteotome hits up against the solid pterygoid bone (signalled by change in the sound)
5. **Osteotomy through lacrimal bone, and anterior ethmoids:** This osteotomy is made at the level of the roof of the antrum (Figures 24b, c). The osteotomy is done by gently tapping on an osteotome or with heavy curved scissors with tips pointed inferiorly. The osteotomy stops at the posterior wall of the antrum
6. **Vertical posterior osteotomy through posterior end of medial wall of antrum anterior to pterygopalatine fossa:** The final posterior vertical cut is made with heavy curved (Mayo) scissors as a downward continuation of the osteotomy in Point 5. It runs through the medial wall of the maxillary sinus,

starting superiorly at the posterior end of the previous osteotomy, and ending at the level of the nasal floor

- The **medial maxillectomy specimen is then removed** by gently levering it inferiorly and laterally with the Mayo scissors while completing the posterior osteotomy, remaining lateral to and preserving middle turbinate
- An **external ethmoidectomy** may now safely be completed under direct vision up to cribriform plate if required
- Carefully remove the paper-thin posterior wall of the maxillary antrum to expose the JNA and the sphenopalatine and/or internal maxillary artery
- Clip/ligate/bipolar the sphenopalatine / internal maxillary artery even if it has been embolised
- Proceed with the resection using blunt and bipolar dissection; suction bipolar electrocautery is first used to ablate feeding vessels along the surface of the tumour; a suction Freer elevator or knife is used to release adhesions
- Dissect tumour off adjacent structures; often it is adherent to septum, sphenoid rostrum, skull base, and nasopharynx
- If tumour extends laterally beyond the pterygopalatine fossa into the infratemporal fossa, then remove the posterolateral antral wall for additional exposure
- Inspect the entire area that was involved with tumour; this may be aided by use of an endoscope
- Obtain meticulous haemostasis
- Apply haemostatic sinus material, such as *Surgicel* to bleeding surfaces
- At the conclusion of surgery, the transected lacrimal sac (Figure 24a) is slit along its longitudinal axis and the edges are sutured to the surrounding tissues or stented to avoid epiphora

Le Fort 1 osteotomy

Le Fort 1 osteotomy with down-fracturing of the palate is suited to tumours limited to the nose, nasopharynx, sphenoid, pterygo-palatine fossa, medial infratemporal fossa and medial cavernous sinus (*Figures 25, 26, Table 4*). (See chapter on [Inferior Maxillectomy](#)) As with other transfacial approaches, effects on facial growth are a concern; Le Fort 1 osteotomy has been reported to result in 30% of predicted vertical growth of the anterior maxilla, though it does not affect horizontal growth and does not cause dental malocclusion. It also causes dental denervation.¹⁰ The maxilla is pre-plated with miniplates along the line of the osteotomy to ensure an accurate repair (*Figure 27a*).

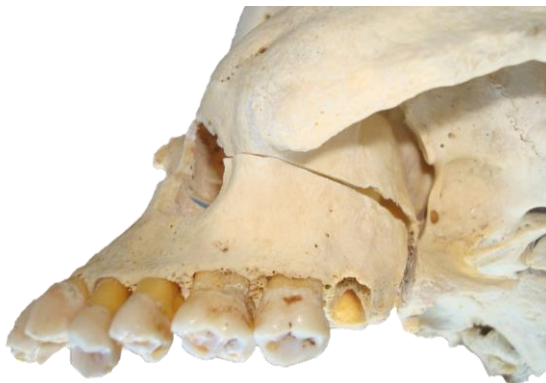

Figure 25: Le Fort 1 osteotomy; posteriorly it passes through the pterygomaxillary fissure

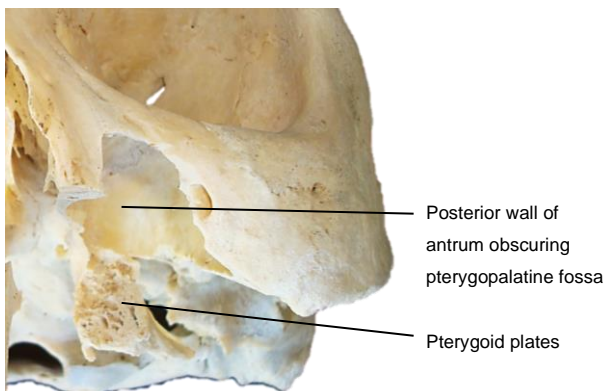


Figure 26: Exposure following down-fracturing of hard palate

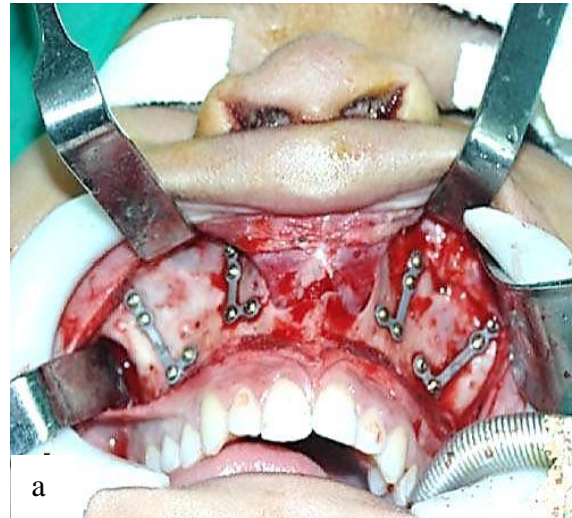


Figure 27a: Maxilla preplated¹¹

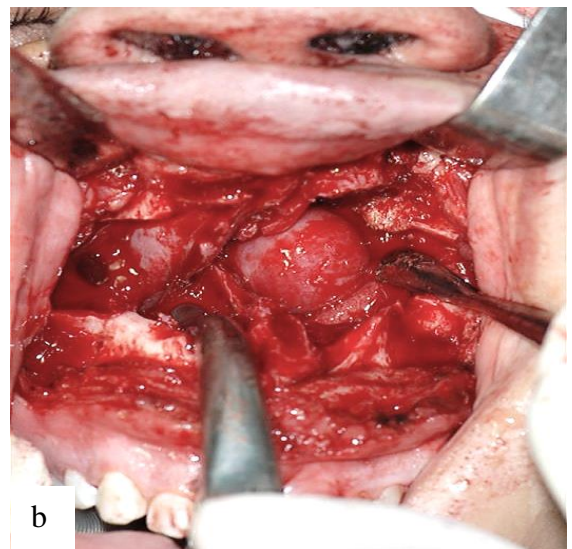


Figure 27b: Maxilla down fractured to expose JNA¹¹

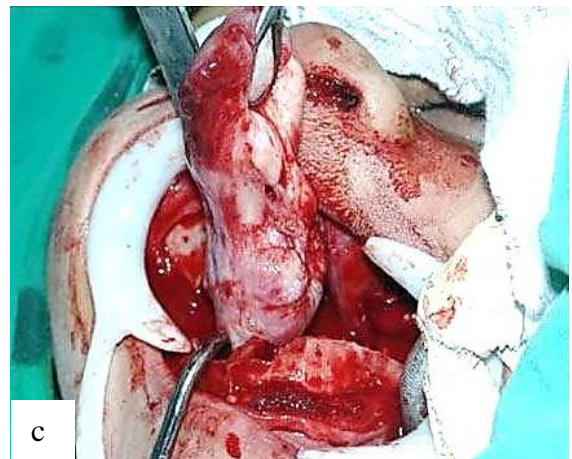

Figure 27c: JNA being delivered¹¹

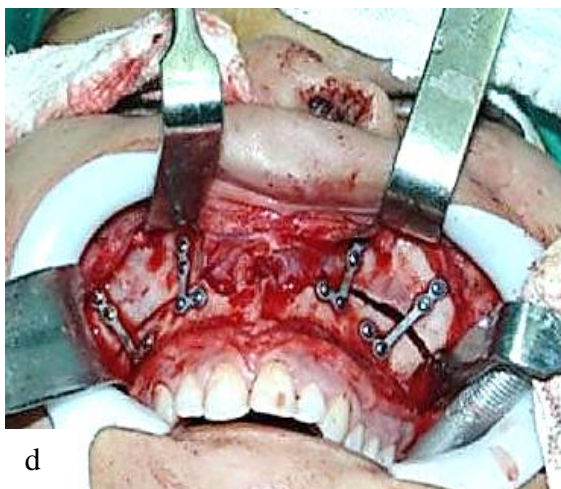


Figure 27d: Plated osteotomy¹¹

Transpalatal approach

This approach can be used for JNAs confined to the nasopharynx, sphenoid and nasal cavity (Table 4). The bony anatomy of the hard palate is illustrated in Figure 28.

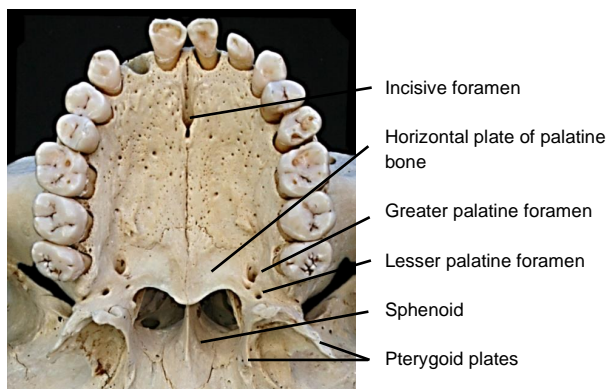


Figure 28 Anatomy of relevant to transpalatal approach

An incision is made in the mucosa of the hard palate, and the thick mucosa is stripped off the hard palate, leaving it attached to the soft palate posteriorly (Figure 29). The soft palate is freed from the posterior edge of the hard palate to access the nasopharynx. The horizontal plate of the palatine bone is removed using a strong backbiter/Kerrison's rongeur /drill to expose the JNA (Figure 29).

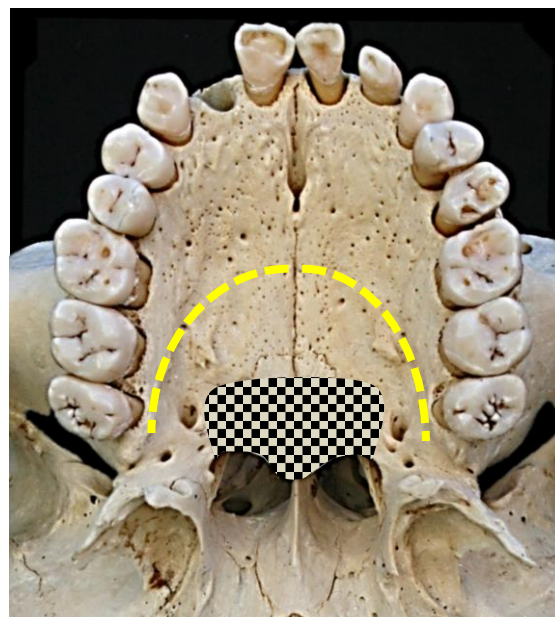


Figure 29: Mucosal incision in hard palate (yellow line) to elevate palatal flap; bone removal to expose tumour (chequered area)

Maxillary swing approach (Figure 30)

This is described in detail in the chapter on [Maxillary Swing approaches](#).

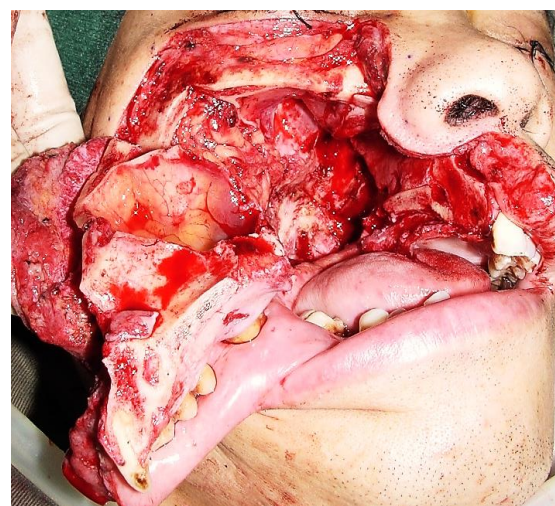


Figure 30: Maxilla has been fully swung laterally exposing nasopharynx; maxilla remains based on soft tissues of cheek

Infratemporal fossa approach

Significant involvement of the infratemporal fossa (Figures 31, 32), cavernous sinus, or middle cranial fossa (Figure 33) requires infratemporal fossa or subtemporal approaches, often combined with an anterior approach. In order to reach the infratemporal fossa, one has to remove the zygoma, and reflect the temporalis muscle (Figures 33-36).

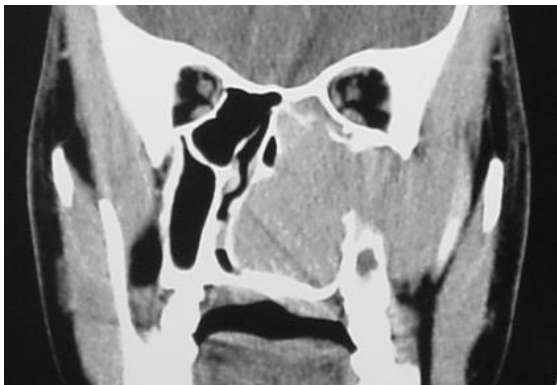


Figure 31: JNA extending to infratemporal fossa

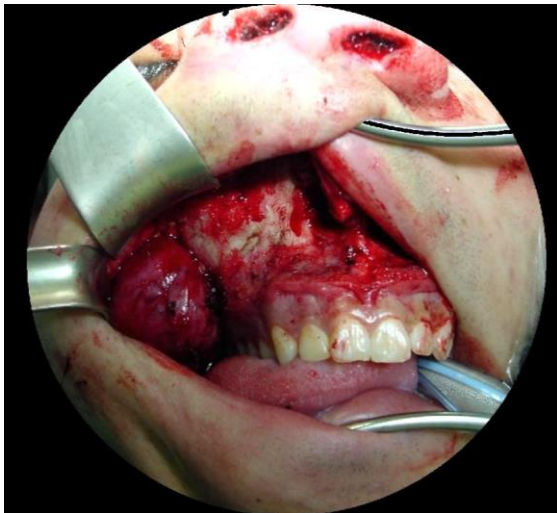

Figure 32: JNA protruding anteriorly from infratemporal fossa

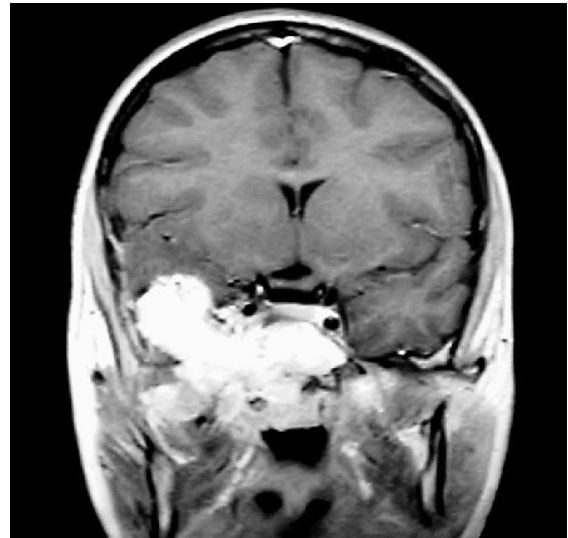


Figure 33: JNA extending to lateral cavernous sinus and middle cranial fossa

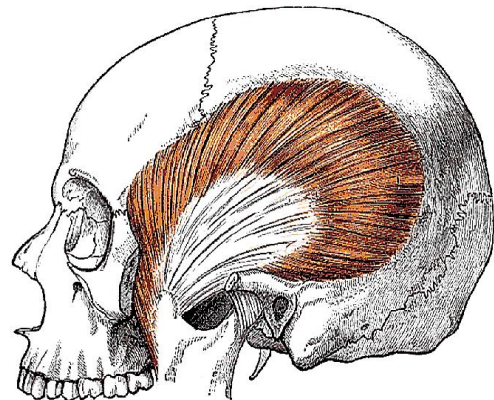


Figure 34: Infratemporal fossa is deep to zygoma (removed) and temporalis muscle

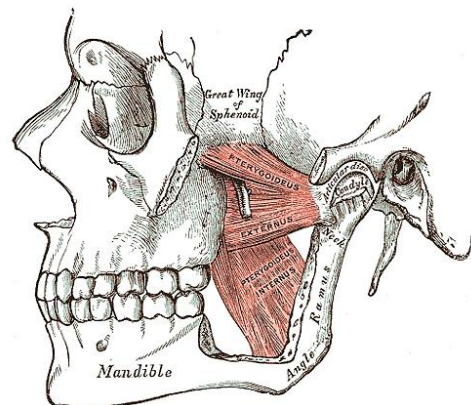


Figure 35: Internal maxillary artery is seen passing between bellies of lateral pterygoid to reach the pterygomaxillary fissure

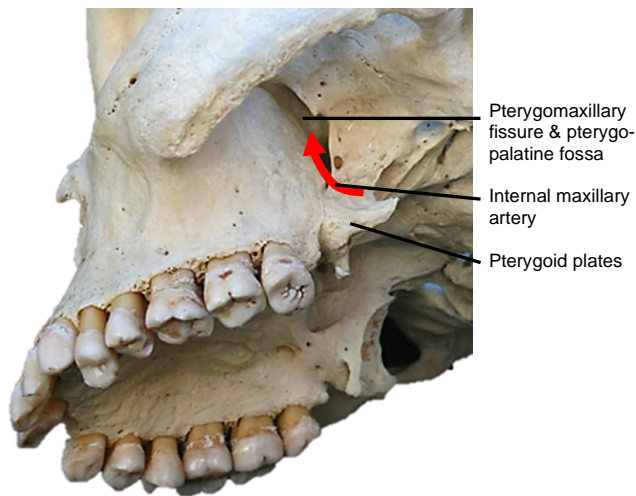


Figure 36: View of infratemporal fossa, internal maxillary artery and pterygo-maxillary fissure

- The surgery is done via a hemicoronal incision commencing in a preauricular skin crease just below the level of the zygoma and placed behind the hairline for cosmetic reasons (*Figure 37*)
- Extend the incision to the temporalis fascia and elevate skin and subcutaneous tissue in the plane on the temporalis fascia (*Figure 37*)
- Elevation in this plane is stopped anteriorly when the superficial temporal fat pad with the facial/temporal branches of the facial nerve are encountered (*Figures 37, 38*)
- Incise the deep layer of deep temporalis fascia in a vertical direction at this point to expose the temporalis muscle
- Dissect anteriorly in a subfascial plane, deep to the fat pad up to the lateral orbital bony rim (anterior margin of temporal fossa)
- Next incise the temporalis fascia about 1cm below the superior temporal line and from the posterior margin of the muscle, down onto the bone (leaving a cuff of fascia on bone permits subsequent suturing of muscle back to its original position)
- Identify the superior aspect of the zygomatic arch along its full length.

This may require forceful inferior retraction of the soft tissues with a Langenbeck retractor (*Figure 39*)

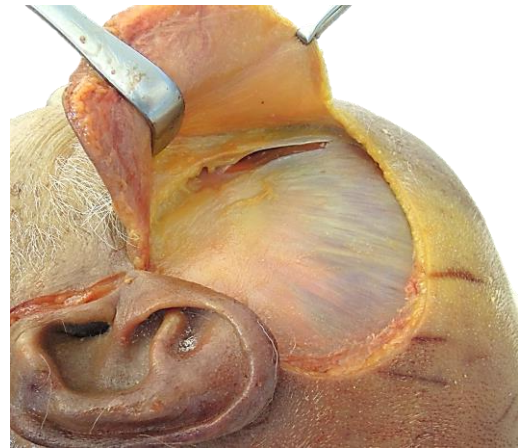

Figure 37: Exposed temporalis fascia and fat pad

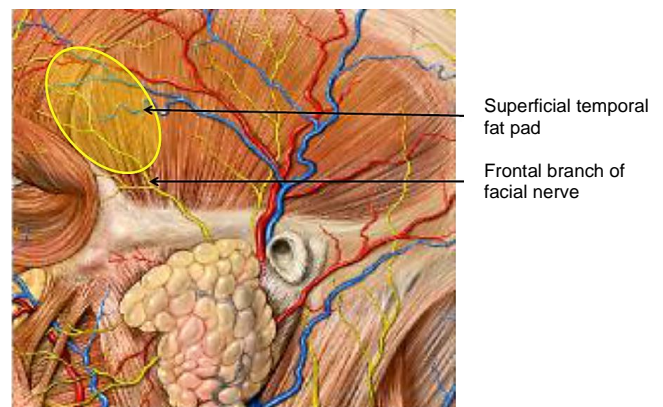


Figure 38: Facial nerve and fat pad

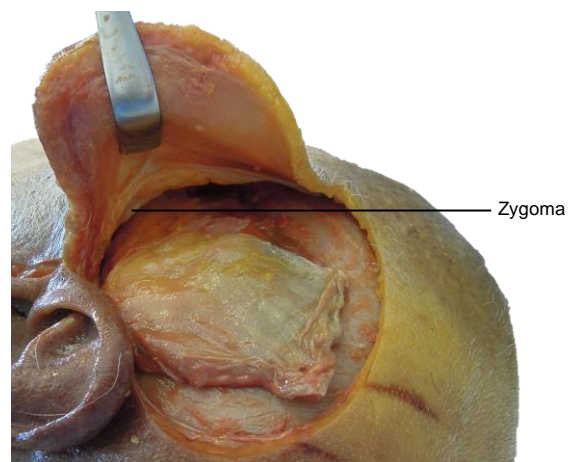


Figure 39: Mobilisation of temporalis muscle and exposure of zygomatic arch

- Incise the two layers of deep temporal fascia along the superior margin of the zygoma, and free the zygoma from the insertion of the masseter muscle
- Osteotomise and remove the zygomatic arch, and preserve it in saline so that it can be plated/wired back later in the procedure
- Elevate the temporalis muscle from the bone of the temporal fossa using either diathermy or a periosteal elevator while remaining hard on the bone (Figure 40)

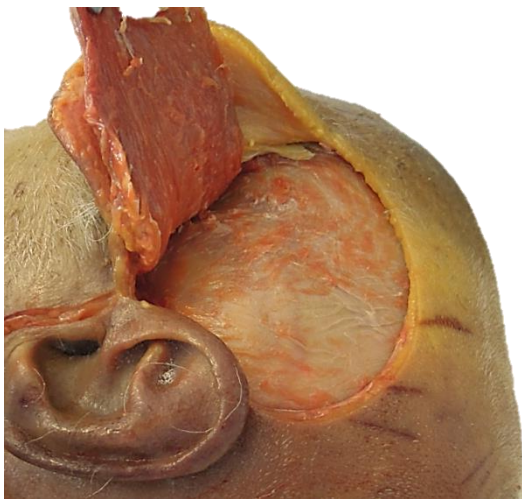


Figure 40: Flap completely elevated from temporal fossa

- Extend the dissection medial to the coronoid process of the mandible that is now readily palpable; the coronoid process of the mandible can be divided and reflected inferiorly for additional exposure

References

1. Herman P, Lot G, Chapot R, Salvan D, Huy PT. Long-term follow-up of juvenile nasopharyngeal angiofibromas: analysis of re-currences. *Laryngoscope* 1999; 109:140-7
2. Pryor SG, Moore EJ, Kasperbauer JL. Endoscopic versus traditional approaches for excision of juvenile nasopharyngeal angiofibroma. *Laryngoscope* 2005; 115: 1201-7
3. Schroth G, Haldemann AR, Mariani L, Remonda L, Raveh J. Preoperative embolization of paragangliomas and angiofibromas. Measurement of intratumoral arteriovenous shunts. *Arch Otolaryngol Head Neck Surg* 1996; 122:1320-5
4. Lee JT, Chen P, Safa A, Juillard G, Calcaterra TC. The role of radiation in the treatment of advanced juvenile angiofibroma. *Laryngoscope* 2002; 112:1213-20
5. Osborn AG. Radiology of the pterygoid plates and pterygopalatine fossa. *AJR Am J Roentgenol* 1979; 132:389-94
6. Andrews JC, Fisch U, Valavanis A, Aeppli U, Makek MS. The surgical management of extensive nasopharyngeal angiofibromas with the infra-temporal fossa approach. *Laryngoscope* 1989; 99:429-37
7. Radkowski D, McGill T, Healy GB, Ohlms L, Jones DT. Angiofibroma. Changes in staging and treatment. *Arch Otolaryngol Head Neck Surg* 1996; 122:122-9
8. Snyderman CH, Pant H, Carrau RL, Gardner P. A new endoscopic staging system for angiofibromas. *Arch Otolaryngol Head Neck Surg* 2010; 136:588-94
9. Fagan JJ, Snyderman CH, Carrau RL, Janecka IP. Nasopharyngeal angiofibromas: selecting a surgical approach. *Head Neck*. 1997 Aug;19(5):391-9
10. Lowlicht RA, Jassin B, Kim M, Sasaki CT. Long-term Effects of Le Fort I Osteotomy for Resection of Juvenile Nasopharyngeal Angiofibroma on Maxillary Growth and Dental Sensation. *Arch Otolaryngol Head Neck Surg*. 2002;128 (8):923-7
11. Avelar RL, de Santana Santos T, Antunes AA, Dourado E Filho JRL. Horizontal Maxillary Osteotomy Ap-

proach for Resection of Juvenile Nasopharyngeal Angiofibroma. *J Craniofac Surg* 2011;22: 1027-30

Suggested video

Goncalves N, Lubbe DE. Juvenile Nasal Angiofibroma (JNA): A case presentation and review of endoscopic surgical technique. *UCT-Africa ENT Virtual video channel*

<https://www.youtube.com/watch?v=iZETRW Ej3wM>

Author

Derek J. Rogers, MD
Pediatric Otolaryngology
Harvard Medical School
Massachusetts Eye and Ear Infirmary,
Boston, MA, USA

Derek_Rogers@meei.harvard.edu

[Disclaimer: The views expressed in this chapter are those of the authors and do not necessarily reflect the official policy or position of the Department of the Army, the Department of Defense, or the US government. MAJ Rogers is a military service member. This work was prepared as part of his official duties. Title 17 U.S.C. 105 provides that 'Copyright protection under this title is not available for any work of the United States Government.' Title 17 U.S.C. defines a "United States Government work" as a work prepared by a military service member or employee of the United States Government as part of that person's official duties]

Author

Christopher J. Hartnick, MD, MS Epi,
Professor
Department of Otolaryngology
Division Director, Pediatric
Otolaryngology
Harvard Medical School
Massachusetts Eye and Ear Infirmary
Boston, MA, USA
Christopher_Hartnick@meei.harvard.edu

Author & Editor

Johan Fagan MBChB, FCS(ORL), MMed
Professor and Chairman
Division of Otolaryngology
University of Cape Town
Cape Town, South Africa

johannes.fagan@uct.ac.za

THE OPEN ACCESS ATLAS OF OTOLARYNGOLOGY, HEAD & NECK OPERATIVE SURGERY

www.entdev.uct.ac.za



The Open Access Atlas of Otolaryngology, Head & Neck Operative Surgery by [Johan Fagan \(Editor\)](mailto:johannes.fagan@uct.ac.za) johannes.fagan@uct.ac.za is licensed under a [Creative Commons Attribution - Non-Commercial 3.0 Unported License](https://creativecommons.org/licenses/by-nc/3.0/)

