

OPEN ACCESS ATLAS OF OTOLARYNGOLOGY, HEAD & NECK OPERATIVE SURGERY



LOCAL AND REGIONAL ANAESTHESIA TECHNIQUES FOR OTOLOGIC (EAR) SURGERY

Alexander Bien, Richard Wagner, Eric Wilkinson

The logistics of performing otologic (ear) surgery in developing countries and in humanitarian settings are challenging. Implementing the use of local anaesthesia to perform middle ear and mastoid surgery in such situations has many advantages.

This article will outline the rationale for local anaesthesia in otologic surgery as well as educate the reader about local anesthetic agents and the anatomy of the ear that allows local anaesthesia to be an effective means under which to perform otologic procedures.

Rationale for Local Anaesthesia

Performing otologic procedures under local anaesthesia - as opposed to general anaesthesia - has many advantages in a humanitarian setting. Depending on the specific setting, the main impetus for performing a procedure under local anaesthesia may be the lack of trained anaesthesia support. In the absence of trained anaesthesia staff in the form of anaesthetists or nurse anaesthetists, local anaesthesia is the safest option. Thus, *safety is a primary advantage*.

Another reason is the potential for the lack of adequate and/or functional anaesthesia machines and monitoring equipment. Not only must there be a functioning anaesthesia machine that can deliver inhaled anaesthetic agents and assume ventilatory functions, but there must also be other equipment to ensure adequate and monitored delivery of these functions. This includes a reliable pulse-oximeter, EKG machine, blood pressure monitor, and end-tidal CO₂ monitor. Even if inhaled agents were not used and adequate anaesthesia was attained with injectable agents alone, such as propofol, most of these “ancillary” monitor-

ing devices would still be needed. Again, this returns to the issue of safety.

Another reason is that of *recovery time and turnover; the ability to perform more cases in a shorter amount of time*. Time is of the essence in the humanitarian setting, even more so than in a Western medical setting. A humanitarian mission may be limited to a certain number of days or even daylight hours. The capacity to perform even *one* additional case in any given day may translate into the benefit of many - depending on the duration of the outreach - more patients. No time needs to be allotted for the reversal of anaesthesia and the monitoring needs during recovery are minimal - limited primarily to observation. Most, if not all, of these concerns are eliminated with the use of purely local anaesthetic.

Neurovascular Anatomy of the Ear

The ear is complex in terms of its neurovascular composition, but an understanding of these elements is crucial in the successful application of local anaesthesia in otologic surgery. With that in mind, it bears mention that the goal of local anaesthesia (with vasoconstrictive agents), especially in ear surgery, is not simply anaesthesia so that the patient feels no pain, but also *haemostasis* so the surgeon feels no pain! For this reason, a discussion of the relevant anatomy for the practice of local anaesthesia in otologic surgery must include not only the neural innervation of the ear but also its vascular supply.

Vascular supply

As evidenced by its brisk bleeding if lacerated and its ability to heal after injury, the auricle has a robust blood supply.

The **external ear** receives its blood supply from the two terminal branches of the external carotid: the **posterior auricular artery** and **small auricular rami of the superficial temporal artery** (Figure 1).

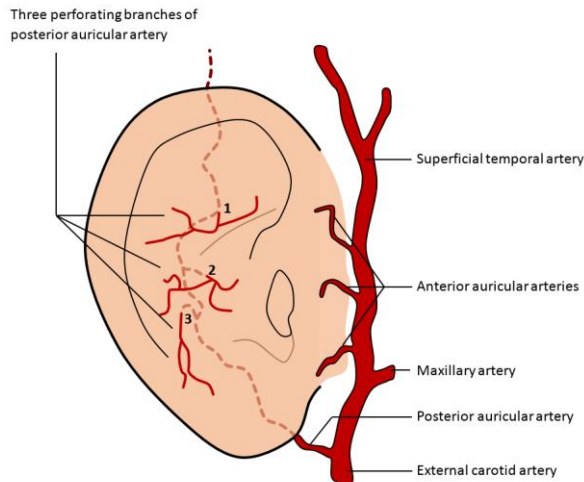


Figure 1: Arterial supply to external ear

These same two arteries supply the external ear canal with the addition of the **deep auricular artery**. The deep auricular artery branches from the first part of the internal maxillary artery, passes through the substance of the parotid gland and behind the temporomandibular joint to penetrate and **supply the medial portion of the external ear canal**.

The **tympanic membrane** receives its blood supply from several sources. Owing to its position anatomically, its vasculature is derived from those vessels supplying the middle ear and external auditory canal. Working from lateral to medial, the outer surface has the same supply as does the medial portion of the external ear canal: the **deep auricular artery**. The deep auricular artery gives off branches that form a **vascular ring** around the tympanic membrane but also gives off a more prominent twig, the **descending or manubrial artery**, that descends along the manubrium of the malleus (Figure 2).

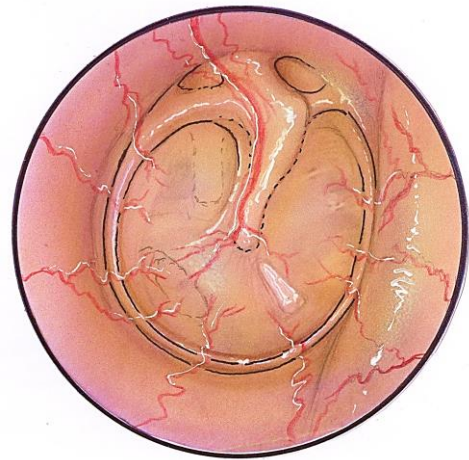

Figure 2: Representation of the arterial supply of the tympanic membrane from both the small peripheral arterioles and the larger manubrial artery, both branches of the deep auricular artery (Adapted from Hollinshead, 1982)

The **medial, or mucosal, surface of the tympanic membrane** is supplied by branches from the **anterior tympanic branch of the internal maxillary artery** and from the **stylomastoid branch of the posterior auricular artery**¹.

The blood supply of the **middle ear and mastoid** arises primarily from the external carotid system. Four arterial contributions arise from the external carotid artery. Two of these contributors are the **anterior tympanic artery** that arises from the internal maxillary artery and the **inferior tympanic artery** that arises from the ascending pharyngeal artery. The other two are the **stylomastoid artery** that arises either from the posterior auricular or occipital arteries, and the **middle meningeal artery** that arises from the internal maxillary artery (Figure 3). After entering through the stylomastoid foramen, the stylomastoid artery gives off the posterior tympanic artery that enters the middle ear, as well as giving off branches to the mastoid air cells. The middle meningeal artery supplies two arteries to the middle ear: the petrosal and superior tympanic arteries. Finally, there can be several bran-

ches off of the internal carotid artery that enter through the caroticotympanic canal to supply the middle ear.

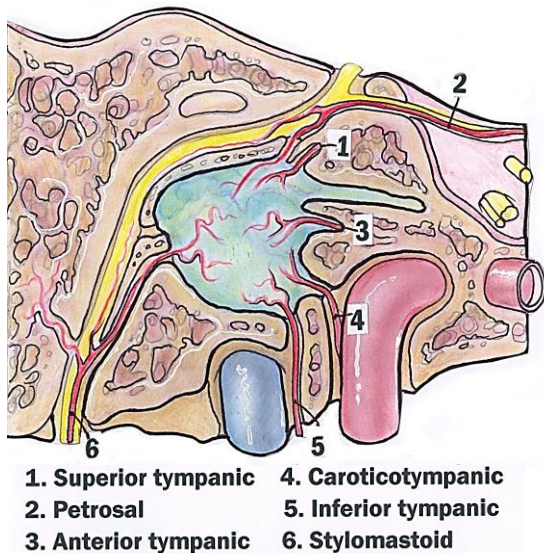


Figure 3: Contributions to the arterial supply of the middle ear (Adapted from Hollinshead, 1982)

Venous drainage of the external ear is via the *superficial temporal* and *posterior auricular veins* into the retromandibular and the external jugular veins respectively (Figure 4). Ultimately, the retromandibular vein splits to drain into the internal and external jugular veins; on occasion, the posterior auricular vein will drain directly to the sigmoid sinus via the mastoid emissary vein¹.

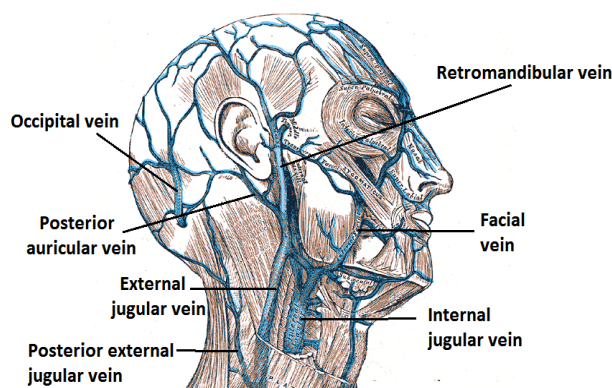


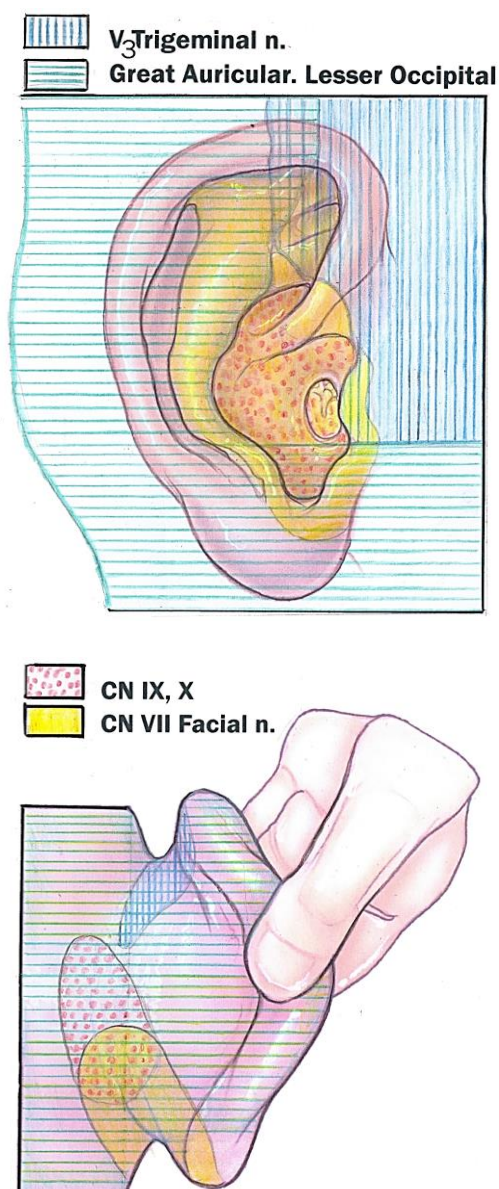
Figure 4: Venous drainage of external ear

Nerve supply

Innervation of the auricle has been explained in exquisite detail elsewhere², but an overview of the main contributing nerves will be undertaken here. Sensation to the external ear is provided by several cutaneous branches of cranial nerves as well as by cutaneous branches of the cervical plexus. This is reflective of the origin of auricular skin that originates from both brachial and post-brachial components¹. There is invariably some overlap in the innervation from person-to-person, but the contributions are relatively constant (Figures 5a, b).

A branch of the mandibular division of the trigeminal nerve (V_3), the auriculotemporal nerve, supplies the anterior portion of the external ear, the crus of the helix, and the tragus. This same nerve supplies the anterior and superior walls of the external auditory canal^{1,3}. A majority of the remaining lateral, posterior, and medial portions of the ear - excluding the concha - are supplied by cutaneous branches of C2 and C3 via the great auricular nerve. The C2 and C3 roots of the cervical plexus also supply the skin overlying the mastoid via the lesser occipital nerve¹.

The concha of the external ear has similarly complex and overlapping sensory innervations. Branches of the 7th (facial), 9th (glossopharyngeal), and 10th (vagus) cranial nerves supply this area. At least two of these cranial nerves (7th and 10th), and possibly the 9th, also supply the posterior external auditory canal. All three of these nerves reach their ultimate points of innervation via the auricular branch (Arnold's nerve) of the vagus nerve. Arnold's nerve arises from the superior jugular ganglion and eventually emerges through the tympanomastoid fissure. Along its course, it picks up the *auricular branch* (not the *tympanic branch*) from the 9th along with a branch



Figures 5a, b: Cutaneous innervation of the lateral and posterior aspects of the auricle by the trigeminal nerve, the cervical plexus, the 7th cranial nerve, and the 9th and 10th cranial nerves (Adapted from Hollinshead, 1982)

from the posterior auricular branch of the facial nerve^{1,3}. In a similar fashion to the external ear, the **tympanic membrane** is innervated by several different nerves (Figures 6, 7). Just as the auriculotemporal branch of V₃ supplies the anterior and superior aspects of the external ear canal, so too does it supply the anterior and superior

aspects of the external tympanic membrane. Along those lines, the 7th, 9th, and 10th cranial nerves innervate the posterior portion of the external auditory canal as well as the posterior portion of the tympanic membrane via the auricular branch of the vagus nerve¹. The medial portion of the tympanic membrane and middle ear are similarly innervated primarily by the tympanic plexus of the glossopharyngeal nerve (Figure 6).

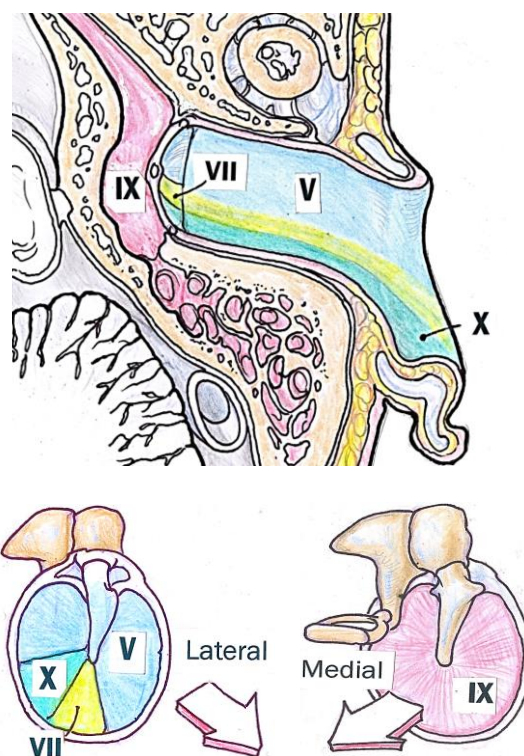


Figure 6: Innervation of external auditory canal, tympanic membrane, and middle ear (Adapted from Hollinshead, 1982)

The topography of nerves on the external surface of the tympanic membrane closely follows that of its vascularity (Figures 4 & 7).

As just mentioned, the middle ear is innervated primarily by the tympanic branch (Jacobson's nerve) of the glossopharyngeal nerve. Upon entering the middle ear during surgery, this nerve can often be clearly seen coursing over the promontory. Jacobson's nerve combines with caroticotympanic ner-

ves from the carotid plexus to form the tympanic plexus (Figure 8).

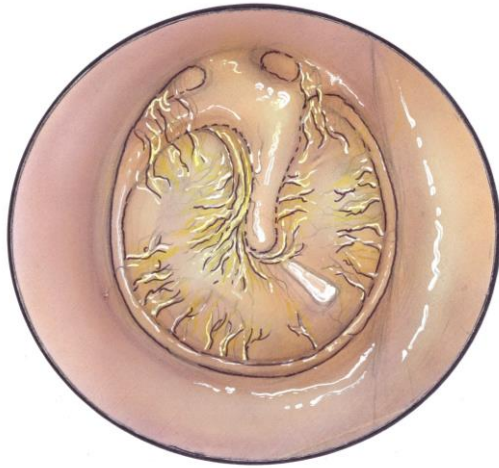

Figure 7: Pattern of neural innervation of the external tympanic membrane. Notice its similarity to the vascular topography of the external tympanic membrane (Figure 3) (Adapted from Hollinshead, 1982)

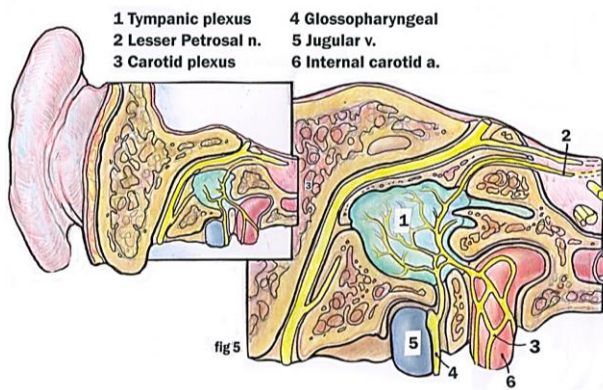


Figure 8: Contributions to tympanic plexus (Adapted from Hollinshead, 1982)

In addition to providing sensory fibers to the mucosa of the middle ear, the tympanic plexus also gives off branches to the entire tympanic cavity, mastoid air cells, and Eustachian tube.

Local Anaesthetic Agents

Having reviewed the neurovascular anatomy of the ear, obtaining some general knowledge of the properties, varieties, and mechanisms of the various local anaesthetics

is useful prior to exploring some specific applications of these agents.

The primary action of local anaesthetics is well-known. The ultimate effect of local anaesthetics is the inhibition of nerve impulse propagation. This blockage occurs because of the inhibition by the local anaesthetic of influx of Na^+ ions, thus preventing an action potential and nerve depolarisation. The precise mechanism that prevents sodium influx is thought to involve specific binding sites within sodium channels located in the cell membrane of the nerve, but the exact mechanism by which this occurs is less clear ^{4, 5}.

Two Main Classes

There are **two main classes** of local anaesthetics based on their chemical structures and the way in which they are metabolised: **amino esters and amino amides**. Technically there is a newer, 3rd class of local anaesthetic, where an agent in one of the other classes is transformed into a novel agent by creating a chiral form. This is done by creating one of two stereoisomers of one of the more traditional local anaesthetics that possess novel properties ⁵.

Ester-type local anaesthetics possess a C-O-O, or ester linkage, while amide local anaesthetics possess an N-H, or amide linkage. Ester-type local anaesthetics are metabolised by the plasma enzyme pseudocholinesterase to paraaminobenzoic acid (PABA). Three of the most commonly used ester-type local anaesthetics are procaine, tetracaine, and cocaine.

The second class of local anaesthetic is composed of those of the **amide-type**. This class is metabolised by microsomal enzymes in the liver. A few of the most commonly used amide-type local anaesthetics are lidocaine, bupivacaine, and mepivacaine ⁴. A stereoisomer of bupivacaine,

called ropivacaine, is a member of the third chiral-form class of local anaesthetics.

Durations of action

In most otologic procedures, the time frame usually does not exceed 3 hours, so any of the more commonly used agents *e.g.* Lidocaine or Mepivacaine, should suffice. The duration of action of lidocaine with epinephrine is the order of 4 hours - more than enough time to complete most otologic procedures. The duration of mepivacaine with epinephrine is even greater - around 6 hours. Both lidocaine and mepivacaine have rapid onset of action. On the other hand, the commonly used ester-type agent, procaine, has a relatively short duration of action - 45 minutes without and about 90 minutes with epinephrine ⁶.

Maximum dose

For 1% (10 mg/mL) lidocaine the maximum dose should not exceed 4.5mg/kg, and used with epinephrine this maximum dose can be as high as 7mg/kg. For mepivacaine, the maximum allowable dosage is 5mg/kg without and 7mg/kg with epinephrine. If a large area of skin is going to be anesthetized, then a relatively low concentration of the agent should be used so as not to exceed the maximum dose allowed. In such a situation, for instance, the concentration of lidocaine could be decreased from 1% or 2% down to 0.5%.

Sensitivity/allergy

Another very important factor to account for in choosing a local anaesthetic is a patient's sensitivity to, or history of allergic reaction to, a given anaesthetic. As a class, the ***ester-type local anaesthetics carrier a much higher risk of adverse, or allergic, reaction*** as compared to the amide class of local anaesthetics. One of the primary metabolites for two of the most commonly used

local anaesthetics in the ester class, procaine and tetracaine, is PABA. Therefore, neither of these agents should be used in patients who are allergic to PABA.

Sedatives and Anxiolytics

Preoperative or intraoperative sedatives or anxiolytic agents can be used in combination with local anaesthesia. Agents such as benzodiazepines (Valium[®]) are very effective anxiolytic drugs and can be used as an adjuvant to local anaesthesia. Other agents such as meperidine (Demerol[®]), an analgesic with sedative properties, or hydroxyzine (Vistaril[®]), an older antihistamine, can also be used. However, if the choice is made to add these other agents to a purely local anaesthetic case, then additional monitoring and resuscitation equipment such as EKG and pulse-oximetry is advisable. Also, rescue drugs such as Narcan[®] should be on hand. Overall, the addition of adjuvant agents adds another layer of complexity, partly detracting from the attractiveness of performing a case under strictly local anaesthesia.

Local Anaesthesia in Ear Surgery

Advantages of Local Anaesthesia in Ear Surgery

Local anaesthesia is an accepted method by which to perform otologic surgery, is used routinely, and has many advantages over general anesthesia.

- Safety is superior to that of general anaesthesia. This includes avoidance of intubation and elimination of the remote possibility of laryngotracheal complications as well as removal of any potential for cardiopulmonary complications related to general anaesthetic agents
- Less bleeding (although most surgeons still use injectable and topical local anaesthesia during general anaesthesia)
- Ability to assess a patient's hearing and

detect any vertigo *during* surgery (especially valuable during stapedectomy)

- Avoidance of a potentially lengthy and/or disruptive emergence from anaesthesia (advantageous in stapes surgery and ossicular reconstruction procedures)
- Less postoperative nausea and vomiting
- Less expensive ³

Auricular Injection Techniques

Several techniques have been advocated, and are generally “variations on a theme”. Hence only a few methods will be addressed in detail.

Plester injection technique (Figures 9-12)

- *Step 1:* Inject the region of the post-auricular fold (*Figure 9*)

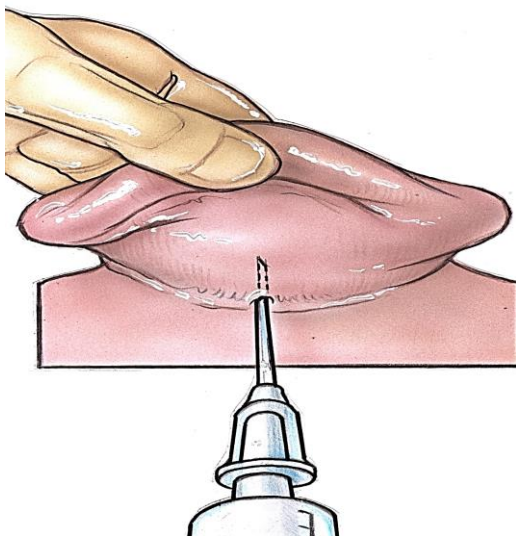


Figure 9: Postauricular injection technique proposed by Plester (From Yung 1996)

- *Steps 2-4:* Without removing the needle in *Step 1*, advance the needle in 3 vectors: directly toward the posterior external ear canal, superior to the external ear canal and inferior to the external ear canal (*Figure 10*)

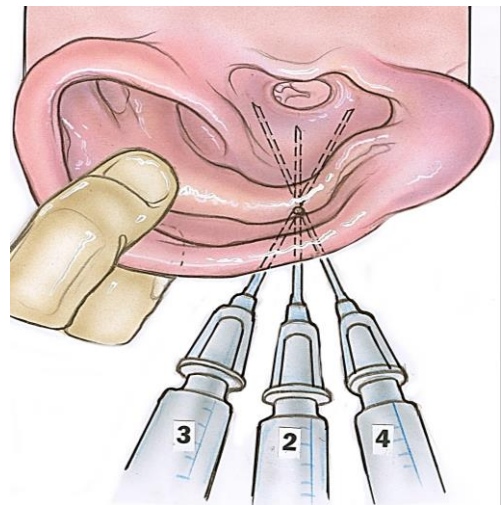


Figure 10: Postauricular injection Steps 2-4 of Plester technique (From Yung 1996)

- *Steps 5 - 8:* Inject the 4 quadrants of the ear canal in a stepwise fashion (*Figures 11 & 12*)⁷. This anaesthetises the external ear canal while at the same time achieving haemostasis of the skin of the ear canal and tympanic membrane. Take care during each of the canal injection steps to avoid the formation of haematomas or vesicles that could impair healing or obscure the tympanic membrane during surgery ⁷

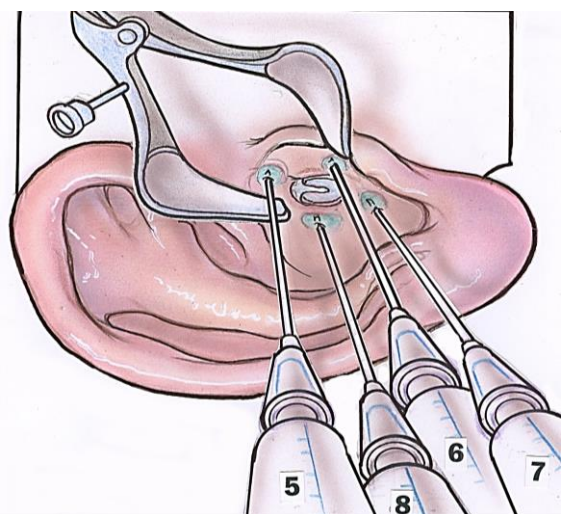


Figure 11: Canal injection steps 5-8 of Plester technique (From Yung 1996)

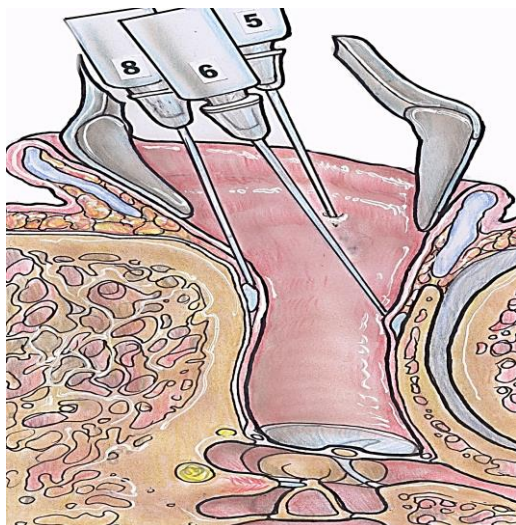


Figure 12: Axial view of canal injection of Plester technique (From Yung 1996)

Fisch injection technique

Fisch's technique uses fewer injection sites and the sites are differently placed ⁵.

- Insert the needle about 1cm behind the postauricular crease at a point halfway between the mastoid tip and the top of the ear
- Pass the needle anteriorly and inferiorly toward the tympanomastoid sulcus and inject local anaesthetic lateral to, but overlying the stylomastoid foramen (Figure 13)
- Direct a 2nd needle pass anterosuperiorly toward the *incisura* and inject more local anaesthetic (Figure 13)
- Wait 10 minutes ³ (In general, this is advisable when working under local anaesthesia also to allow more time for vasoconstriction to occur)
- Inject the external ear canal; Fisch's technique differs from that of Plester in that only one canal injection is performed initially. This initial injection is placed superiorly in the region of the tympanosquamous suture line. After this initial canal injection, the other areas of the canal are tested for sensitivity and the other quadrants are injected only if needed

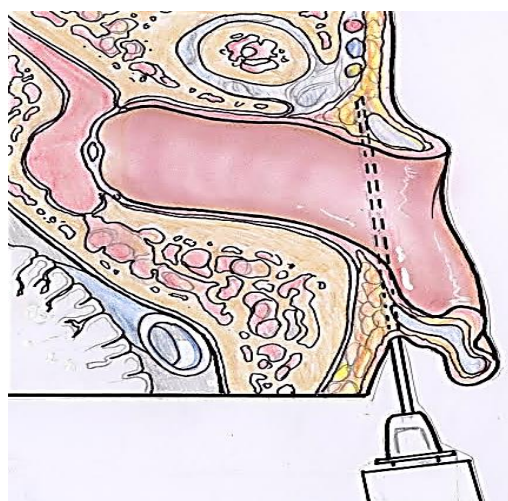
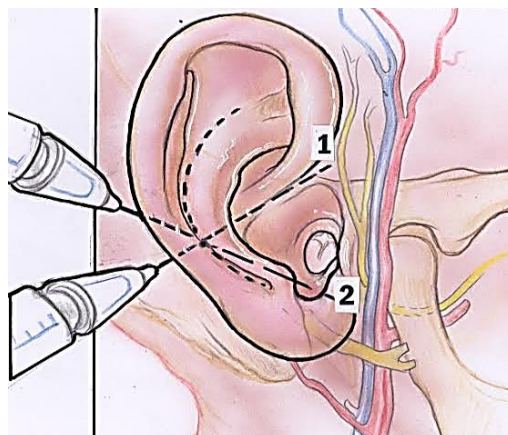


Figure 13: Fisch postauricular injection technique (from Lancer and Fisch 1988)

A drawback of the Fisch technique is a high risk of temporary facial nerve paresis due to injection in the region of the stylomastoid foramen; this can be very distressing for the patient and surgeon alike. Using this injection technique in a series of 32 patients, *Fisch* reported that 97% developed a temporary postoperative facial weakness. For this reason we recommend that no injections be administered below the level of the external auditory canal.

Additional Intraoperative Analgesia

More local anaesthetic can be administered in any of these local anaesthetic techniques if the patient feels pain during the surgery. However the surgeon should en-

sure that a running total of the amount of local anaesthetic agent is kept so as not to exceed the maximum allowable dose.

Jacobson's nerve (supplies the middle ear mucosa) can be anaesthetised if a patient experiences pain during the *middle ear part of the procedure*, by the placing a cotton ball or gelfoam soaked with 1% lidocaine or 4% tetracaine ⁷ on the promontory.

Field blocks

Field block is a form of regional anaesthesia that takes advantage of the subcutaneous course of somatosensory cutaneous nerve branches. A larger area can be anaesthetized with fewer injections by infiltrating the region of the course of any given nerve. Ideally, this injection is done in an area more proximal than the area in which an incision is going to be made so as to provide anaesthesia distal to the injection site. It requires less anaesthetic agent to be used as well as keeping the incision site undistorted ⁵. Field blocks require an understanding of the anatomy of auricular innervation. Nerves amenable to a field block for ear surgery are the auriculotemporal, greater auricular, and the lesser occipital nerves (*Figure 14*).

Auriculotemporal nerve field block

The auriculotemporal nerve exits from the parotid gland in front of the ear (*Figure 15*). The area to infiltrate is located by palpating the superficial temporal artery as it passes over the zygoma (*Figure 14*). The injection is placed in between this point and the *incisura* - near the root of the zygoma. About 2-3 ml of local anaesthetic is used to block the nerve ⁵.

V3 nerve regional block

A more complete, truly regional auriculotemporal nerve block can be achieved by

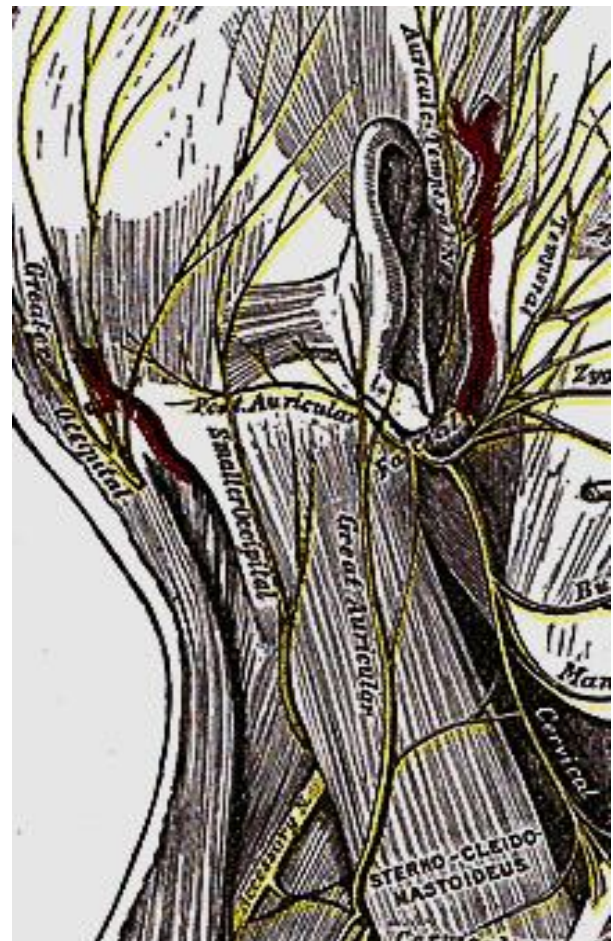


Figure 14: Nerves suitable for field block: greater auricular, auriculotemporal and lesser ("smaller") occipital nerves; note superficial temporal artery

performing a V₃ nerve block. This block provides excellent anaesthesia over the bulk of the cheek along with the upper pre-auricular and auriculotemporal hair covered regions. The anaesthetised area abuts the region supplied by the great auricular nerve more posteriorly ⁸.

- Palpate the sigmoid notch of the mandible as an initial landmark. The notch is located inferior to the zygomatic arch about 2.5 cm anterior to the tragus
- While placing a finger in the area of the notch and asking the patient to open the mouth; the mandibular condyle is felt sliding under the examiner's finger
- Ask the patient to close the mouth; the examining finger will stay in the notch

- Mark this point with a marking pen
- Inject a small volume of local anaesthetic in this area before proceeding to perform the block
- Insert a 5cm spinal needle perpendicular to the skin at the site where you marked the sigmoid notch (*Figure 15*)

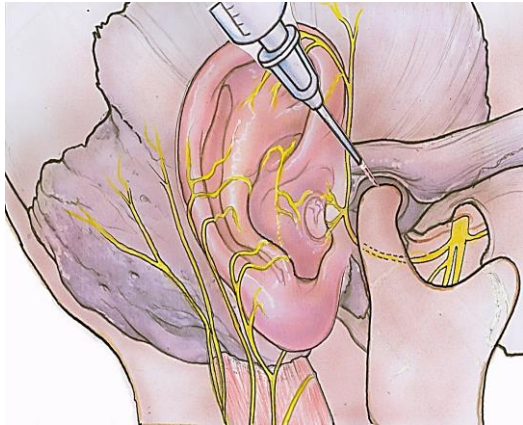


Figure 15: Auriculotemporal nerve block.

- At a depth of about 4cm, the needle will hit the lateral pterygoid plate
- Withdraw the needle almost to the skin and redirect it 1cm posterior to the 1st pass, and to the same depth
- Aspirate to ensure that the tip of the needle is not in a vessel
- Slowly inject 3-4ml local anaesthetic

Greater auricular nerve field block

The great auricular nerve block numbs the lower third of the ear and the lower post-auricular skin (*Figure 14*). We describe two techniques below.

The first technique blocks the nerve more proximally and is therefore more of a regional block.

- Identify the anterior and posterior borders of the sternocleidomastoid muscle, and draw parallel lines to delineate these borders of the muscle
- Draw a third line parallel to and in the middle of these two lines to mark the

middle of the muscle

- Draw a line from the inferior edge of the external auditory canal 6.5cm inferiorly to meet the midline mark on the sternocleidomastoid
- At this point, inject a few ml of local anaesthetic ⁸.

The alternative technique takes advantage of the fact that the nerve exits from around the posterior border of the sternocleidomastoid muscle and then splits into anterior and posterior branches (*Figure 14*). By locating the mastoid tip and injecting local anaesthetic both anterior and posterior to the mastoid the two branches of the nerve can be blocked ⁵.

Lesser occipital nerve block

A lesser occipital nerve block anaesthetises most of the skin overlying the mastoid.

- Locate the posterior border of the origin of the sternocleidomastoid muscle at the base of the skull (*Figure 14*)
- Introduce a needle at this point directly posteromedial and slightly cephalad until the bone of the calvarium is reached
- Withdraw the needle by few millimeters
- Aspirate to ensure that the tip is not in the occipital artery
- Inject a few ml of local anaesthetic

Vagus nerve field block

Although usually anaesthetised during the infiltration of other regions of the post-auricular sulcus, the auricular branch of the vagus can be pinpointed and blocked by injecting local anaesthetic where the nerve exits the skull base between the mastoid process and the tympanic plate ⁹.

Other nerves

Even though the concha and middle ear mucosa are innervated by the 7th and 9th cranial nerves, these nerves are not amena-

ble to a regional block. Anaesthesia in the distribution of these nerve can be achieved by local infiltration of the external ear canal and topical anaesthesia to the middle ear.

Effectiveness of Local Anesthesia for Middle Ear Surgery

Several authors have commented on the effectiveness of local anaesthesia for otologic surgery. *Caner* reported on 100 consecutive patients undergoing various middle ear procedures under local anaesthesia with IV sedation, including mastoidectomy¹⁰. In this paper, 96% of patients who underwent stapes surgery or tympanoplasty alone said that they had no pain during surgery; of all patients 22% said that pain was distressing. The most distressing experiences were anxiety (44%) and noise created by the procedure (33%). However 73% of patients in this study said they would have a similar operation done again under local anaesthesia. Furthermore, only one patient had a transient facial weakness. In a similar paper by *Yung*, 108 patients that underwent various otologic procedures including mastoidectomy reported similarly favourable results⁷. The most frequent complaints were that of noise during the operation (30%) and anxiety (24%). Interestingly, otalgia was reported as the lowest specified discomfort (2%). As in *Caner's* paper, a high percentage (89%) reported that they would prefer local anaesthesia for a similar procedure. *Lancer and Fisch* also reported a high success rate with local anaesthesia and that both patients and surgeons were highly satisfied with local anaesthesia that there had been no adverse effects³. One major concern of the latter paper was the 97% rate of transient (partial to total) facial nerve paralysis. Although transient, it was still unpleasant for a significant number (55%) of patients. These few studies corroborate the notion that otologic surgery done under local anaesthesia is not only an effective technique, but was acceptable to

both patient and surgeon. It should be noted, however, that in all these studies adjuvant sedation was used in addition to local anaesthesia.

References

1. Hollinshead WH. Anatomy for surgeons: Vol 1. The head and neck. Philadelphia: Lippincott Williams & Wilkins; 1982
2. Peuker ET, Filler TJ. The nerve supply of the human auricle. *Clin Anat* 2002; 15:35-7
3. Lancer JM, Fisch U. Local anesthesia for middle ear surgery. *Clin Otolaryngol* 1988;13:367-74
4. Auletta MJ, Grekin RC. Local anesthesia for dermatologic surgery. New York: Churchill Livingstone; 1991
5. Raj PP. Textbook of regional anesthesia. New York: Churchill Livingstone; 2002
6. McLeod IK, Gallagher DJ III, Revis DR, Seagle MB. "Local Anesthetics." eMedicine. July 22, 2008. May 28, 2010
<http://emedicine.medscape.com/article/873879-overview>
7. Yung MW. Local anesthesia in middle ear surgery: survey of patients and surgeons. *Clin Otolaryngol* 1996;21: 404-8
8. Zide BM, Swift R. How to block and tackle the face. *Plast Reconstr Surg* 1998;101:840-51
9. Cousins MJ, Bridenbaugh PO. Neural blockade in clinical anesthesia and management of pain, 3rd Ed. Philadelphia: Lippincott-Raven; 1998
10. Caner G, Olgun L, Gültekin G, Aydar L. Local anesthesia for middle ear surgery. *Otolaryngol Head Neck Surg* 2005; 295-7

Relevant Open Access chapter: Otolaryngology outreach surgery in developing countries under local and regional anaesthesia: Techniques and pitfalls
<https://vula.uct.ac.za/access/content/group/ba5fb1bd-be95-48e5-81be-586fbaeba29d/Otology%20outreach%20surgery%20techniques%20under%20local%20and%20regional%20anaesthesia.pdf>

Authors

Alexander G. Bien, M.D.
St. Louis
Missouri, USA
bienag@gmail.com

Richard Wagner, M.D., F.A.C.S.
Director
Global ENT Outreach
Coupeville, WA, 98239, USA
rwagner@geoutreach.org

Eric P. Wilkinson, M.D., F.A.C.S.
House Clinic
2100 W. Third Street, #111
Los Angeles, CA 900 USA
ewilkinson@hei.org

Editor

Johan Fagan MBChB, FCS(ORL), MMed
Professor and Chairman
Division of Otolaryngology
University of Cape Town
Cape Town, South Africa
johannes.fagan@uct.ac.za

THE OPEN ACCESS ATLAS OF OTOLARYNGOLOGY, HEAD & NECK OPERATIVE SURGERY

www.entdev.uct.ac.za



The Open Access Atlas of Otolaryngology, Head & Neck Operative Surgery by [Johan Fagan \(Editor\) johannes.fagan@uct.ac.za](mailto:johannes.fagan@uct.ac.za) is licensed under a [Creative Commons Attribution - Non-Commercial 3.0 Unported License](https://creativecommons.org/licenses/by-nc/3.0/)

