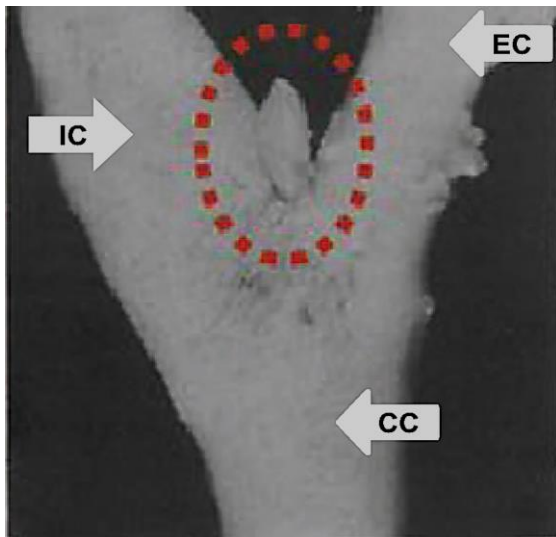




## RESECTION OF EXTRATEMPORAL PARAGANGLIOMAS INCLUDING CAROTID BODY AND GLOMUS VAGALE TUMOURS

Johan Fagan & Vincent Vander Poorten

Paragangliomas, also known as glomus tumours or chemodectomas, are neuroendocrine tumours that originate from glomus cells in paraganglia. They are derived from the embryonal neural crest. The cells are part of the sympathetic nervous system and serve as chemoreceptors. They are located in the vascular adventitia of blood vessels which include the carotid bodies in the carotid artery bifurcation (*Figure 1*).



*Figure 1: Carotid body within carotid bifurcation; it is equivalent to the size of a grain of rice ([Khan Q, Heath D, Smith P. Anatomical variations in human carotid bodies. J Clin Pathol. 1988;41:1196–99](#))*

Paragangliomas occur within the skull base (glomus jugulare, glomus tympanicum), the parapharyngeal space (carotid body tumours, vagal paragangliomas), the larynx and the neck, as well as in the chest and the abdomen. In the head and neck, the carotid body location is most frequent, followed with decreasing frequency in jugular, tympanic and vagal locations. The incidence and prevalence in populations of these rare head and neck tumours remains

unclear, as most are benign tumours not captured by cancer registries. The reported proportion of malignant paragangliomas is 6 - 19%. The malignant nature is demonstrated only by imaging studies showing local invasion, regional or distant metastasis, since the histological appearance of malignant paragangliomas is identical to that of benign tumors <sup>1</sup>.

Regarding the genetic basis of these tumours, about 90% of paragangliomas are sporadic, but in 1 in 10 patients a mutation in the gene coding for succinate dehydrogenase (SDH) subunits (SDHD, SDHB, SDHC) is observed. These patients typically develop multifocal paragangliomas already under 40 years of age, and also present with *phaeochromocytomas*. The latter are neuroendocrine tumours of the adrenal medulla and are closely related to paragangliomas. Unlike paragangliomas they are chromaffin positive and hence secrete catecholamines.

This chapter focuses on the surgical management of extratemporal paragangliomas of the head and neck. Even though surgery remains the mainstay of therapy for easily resectable paragangliomas, many of these tumours are very slowly growing, or do not even grow at all; hence a watchful waiting approach with serial imaging (“Wait and See approach”) may be preferable. Another treatment modality to be considered is irradiation.

### Surgically relevant issues

#### *Not all paragangliomas need surgery*

On the one hand, an initial *wait-and-scan policy* can be justified for many patients

based on the slow growth rate, with half of tumours not increasing in volume during long-term follow-up <sup>2</sup>. In a recent study of cervical paragangliomas followed up for a mean of 5yrs (1-17ys), 42% tumours remained stable, 38% grew, and 20% reduced in size. In those that grew, the mean growth was only 2mm p.a. <sup>3</sup>.

On the other hand, in documented volume-increasing lesions, both **radiotherapy** and **surgery** are valid options.

**Radiotherapy** can consist of Intensity Modulated Radiotherapy (IMRT) using a moderate-dose of 44-50 Gy in 22-25 fractions <sup>1</sup>, or stereotactic radiosurgery <sup>4</sup> in selected very small skull base lesions.

Although radiotherapy is not curative, 10-year local control rates using RT of 94% and higher have been reported <sup>5, 6</sup>. Radiotherapy, however, is associated with a (<1%) risk of radiation-induced malignancy, and the natural course of tumour growth mentioned above does question whether the purported benefits of radiation have in fact been overstated. Anyhow, this modality should - like surgery - only be considered in paragangliomas with a documented growth on serial scanning.

Given the potential complications, **surgery** is best reserved for limited paragangliomas where minimal morbidity is expected. Typically, these are the carotid body tumors that are classified as *Shamblin* Group I (small, easily dissected from the vessels) and Group II (glomus tumor partially sur-rounding the vessels – see below). The former constitutes 70% of paragangliomas. For all other tumors (Group III carotid body tumors and vagal – jugular – tympanic paragangliomas), iatrogenic postoperative cranial nerve deficits are hard to avoid. A recent review estimated the prevalence of complications in surgically treated carotid paraganglio-

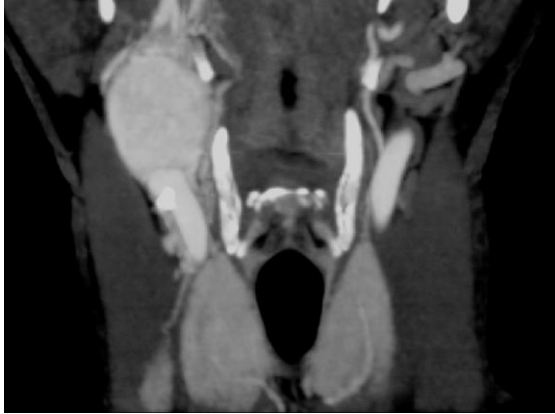mas as 22% postoperative cranial nerve deficits, 3% strokes, and 1% perioperative deaths <sup>7</sup>. Reviewing the literature on vagal and jugular paragangliomas, the same authors concluded that on average 1 extra postoperative cranial nerve deficit occurs per patient operated, which is much more than the 8 post-treatment cranial nerve deficits per 100 patients treated with radiotherapy, at a comparable local control rate of 80-90% for both modalities. The authors conclude that, compared to surgery, radiotherapy results in comparable tumour control, but significantly less morbidity. Choosing between the two modalities, one should consider the patient's age, tumour size and Shamblin type, observed tumour growth and cranial nerve function at presentation, and eventually catecholamine production, in order to maximally safeguard quality of life.

Therefore, patients with paragangliomas without features of malignancy, and in the absence of catecholamine induced chronic hypertension and its negative long-term cardiovascular effects, should be given the option of observation. This applies especially to patients with high surgical or anaesthetic risk, or with asymptomatic vagal paragangliomas where resection is certain to cause vagus nerve (and probably also hypoglossal) paralysis.

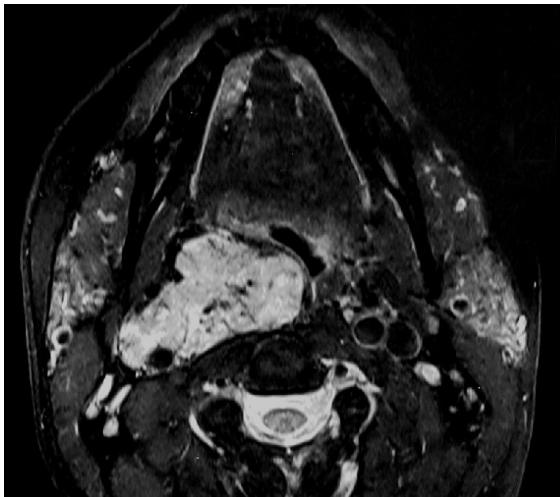
### **Vascularity**

The extreme vascularity of paragangliomas may make surgery challenging. With intratemporal paragangliomas this manifests as pulsatile tinnitus, and a red vascular mass may be visible behind an intact tympanic membrane. In the neck it may manifest as a pulsatile mass in the region of the carotid bifurcation. CT typically shows contrast enhancement (*Figure 2*) and signal flow voids may be evident on MRI (*Figure 3*). Angiography shows a rich vascular network (*Figure 4*). Given the high diagnostic

accuracy of modern imaging, attempts at taking biopsies from these lesions is considered to be contraindicated.



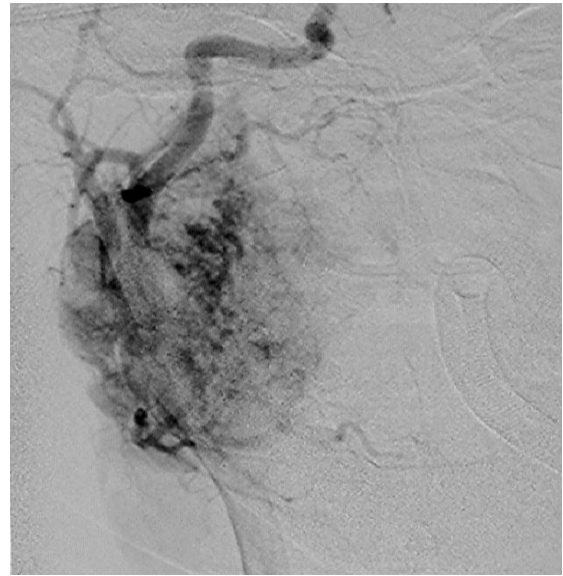
*Figure 2: Coronal CT scan shows contrast enhancement of a carotid body tumour*



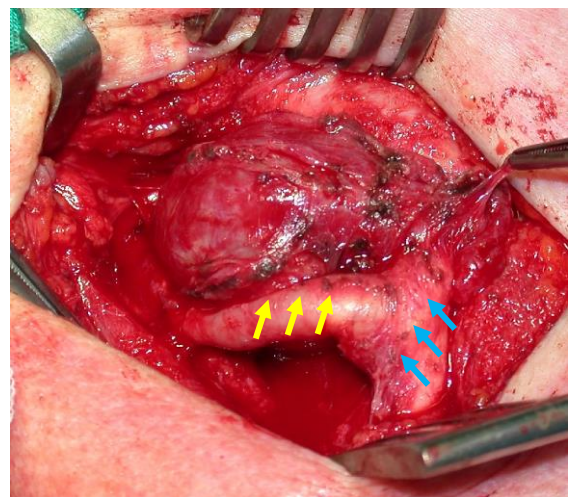
*Figure 3: MRI shows (black) signal flow voids of carotid vessels and smaller arteries within a carotid body tumour*

### ***Lack of encapsulation***

Especially with carotid body tumours, thin-walled vessels cover the surface of the tumour and blend with the adventitia covering the carotid vessels. Because of their thin walls, monopolar cautery is ineffective; hence the need to dissect the tumour from the carotid arteries in a subadventitial plane and to control bleeding from the multitude of thin-walled vessels with bipolar cautery or with multiple ties (*Figure 5*).



*Figure 4: Angiogram illustrating vascularity of a carotid body tumour*



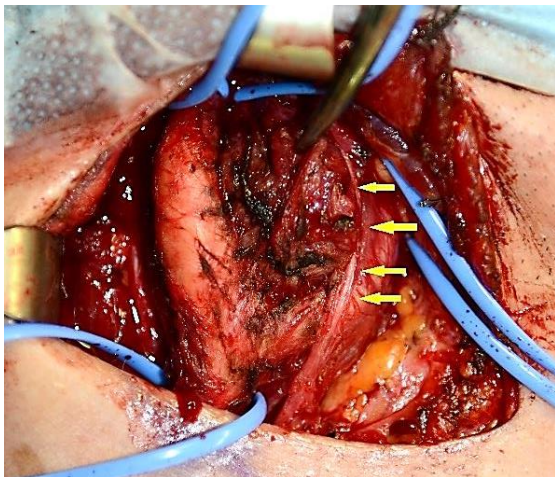
*Figure 5: Bipolar cautery has been used to achieve haemostasis, and dissection is maintained in a subadventitial plane (yellow arrows) on the internal carotid artery; retained adventitia indicated by blue arrows (right neck)*

### ***Nerves at risk of injury***

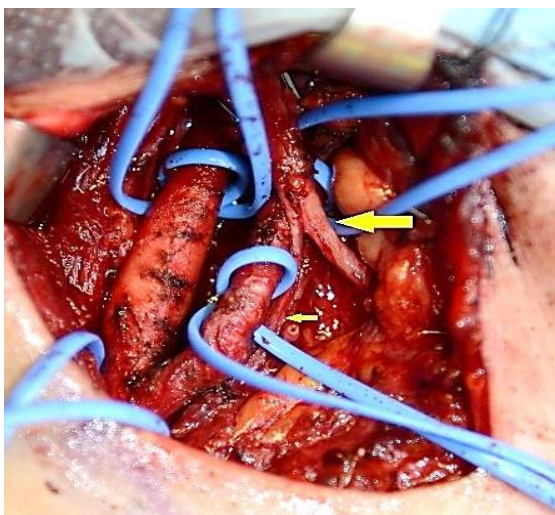
It is not uncommon for the hypoglossal (*Figure 6a*), descendens hypoglossi (*Figure 6b*), superior laryngeal, vagus, and accessory nerves and the sympathetic trunk to be involved by a carotid body tumour. With glomus vagale tumours the vagus nerve is at significant risk of permanent



surgical injury, but also the hypoglossal nerve and the sympathetic chain may be embedded within a vagal paraganglioma. These nerves need to be carefully identified beyond the confines of the tumour before commencing the tumour resection so that they can be dissected free and preserved if at all possible.



*Figure 6a: After vessel-loop control of the common, internal and external carotid arteries, subadventitial dissection of this right sided Shamblin type I carotid body tumour proceeds using bipolar cautery; arrows indicate descends hypoglossi branch to ansa cervicalis*



*Figure 6b: Situation after removal of the tumour shows the preserved hypoglossal nerve (big arrow) and descendens hypoglossi (small arrow)*

### ***Catecholamine secretion***

Phaeochromocytoma-like symptoms due to catecholamine secreting tumours occur in 1–3% of patients with paragangliomas in the head and neck, and manifest with palpitations, hypertension, headaches, and sweating. If left unattended, heart failure and arrhythmia will ensue in the long run. Failure to detect catecholamine secretors can lead to life-threatening haemodynamic instability during embolisation or surgery. Perioperative optimisation includes adrenergic receptor blocking agents. Hence the need to test for free catecholamines so that secretors can be optimised preoperatively. Alternately one can test for urinary metanephrine levels or urinary vanillylmandelic acid (VMA) levels (least expensive, but least specific). Because secreting paragangliomas in the head and neck are so uncommon, raised catecholamines should prompt one to exclude the presence of a phaeochromocytoma. Proton pump inhibitors may cause false positive elevation of serum chromogranin A; if elevated, PPIs should be discontinued for a week and the test repeated.

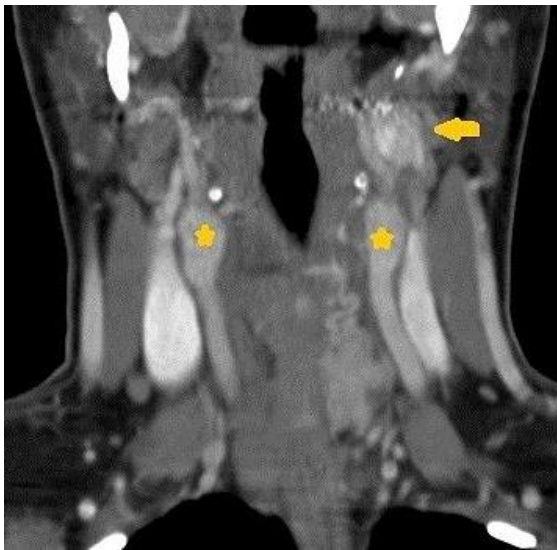### ***Genetic screening***

A family history is associated with increased likelihood of multiple paragangliomas and of patients presenting at an earlier age. There are various genetic mutations of which 10% are hereditary<sup>8</sup>.

Patients with a positive family history and those with multiple paragangliomas must be offered genetic testing, although nowadays it could be argued that all patients deserve genetic testing as often an SDH mutation is found despite a negative family history. Paragangliomas also occur in MEN syndromes types 2A and 2B.

### ***Multiple paragangliomas***

About 10% of carotid body tumours are bilateral. Multiple paragangliomas should be suspected in patients with a positive family history and with head and neck paragangliomas that have raised catecholamines (*Figure 7*).



*Figure 7: Bilateral carotid body tumours (\*) and left vagal paraganglioma (arrow) in a patient with a SDH-D mutation. Following this diagnosis the patient's brother was also diagnosed with an SDH-D mutation and multiple paragangliomas*

### **Radiological investigations**

Radiological investigations may determine the following:

#### ***Confirm that it is a paraganglioma***

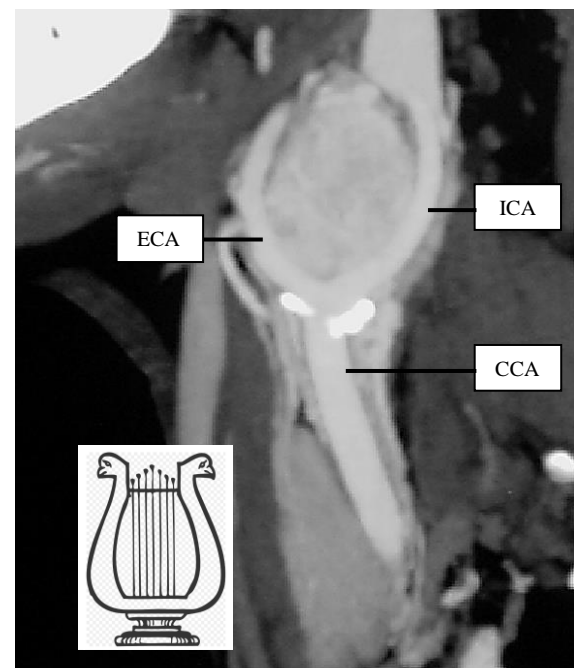
CT, MR and MR angiography of the head and neck have such typical findings, that they obviate the need for a (hazardous) biopsy. Imaging studies reveal the location, extent, relation to the great vessels, and unsuspected coexistent paragangliomas at other sites.

**CT with contrast** typically shows a hyperaemic mass (*Figures 2, 8*). A small paraganglioma may however not enhance if peak-tumour opacification is mistimed; the mass may then be mistaken for a schwannoma or a lymph node. Metastatic papillary carcinoma of the thyroid may also enhance with contrast.

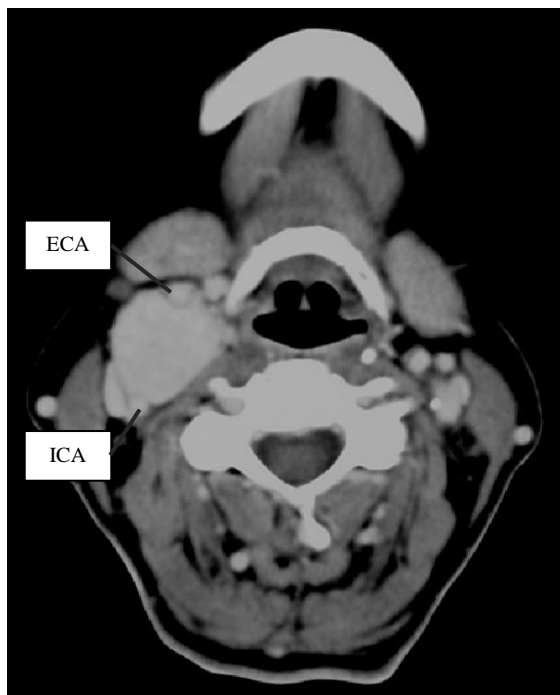**MRI** reveals a hyperaemic mass with signal flow voids on T2 (*Figures 3, 9b*) sometimes giving a classic *salt-and-pepper sign*.

#### ***Carotid body tumour vs. vagal paraganglioma***

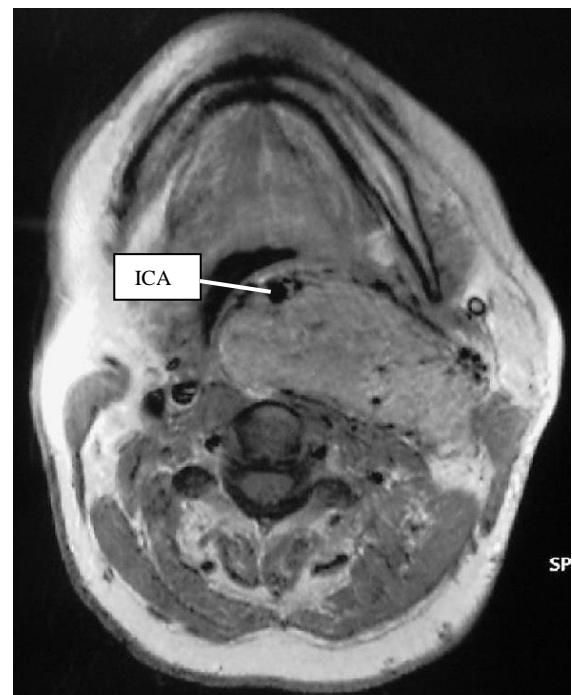Carotid body tumours classically splay the internal and external carotid arteries (Lyre sign) (*Figures 8a, b*); vagal paragangliomas displace the internal and external carotid artery anteriorly (*Figures 9a, b*).



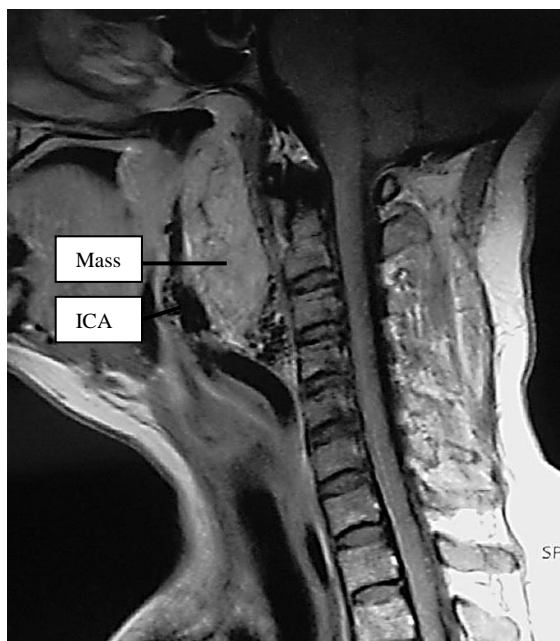
*Figure 8a: Splayed carotid bifurcation (Lyre sign)*



*Figure 8b: Carotid body tumours splay the internal and external carotid arteries*



*Figures 9b: Vagal paraganglioma typically displaces the internal carotid artery anteriorly*



*Figure 9a: Vagal paraganglioma displacing the internal carotid artery anteriorly*

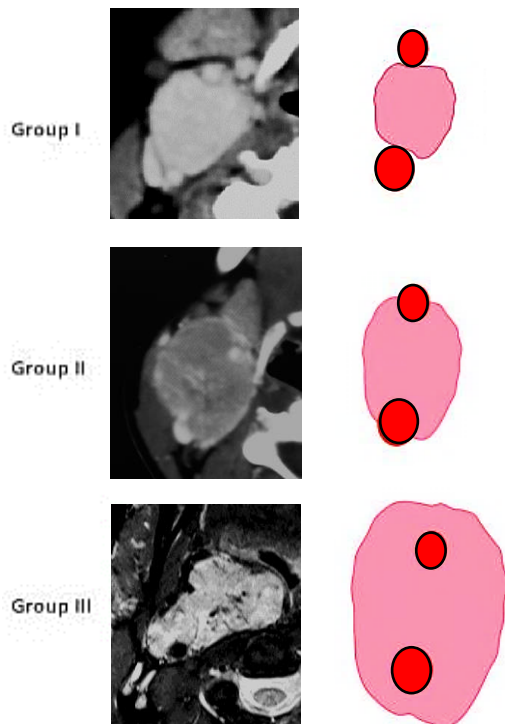
### **Resectability**

Resectability is largely determined by the degree of involvement and encasement of the common and internal carotid arteries. Preoperative classifications however have limitations as tumour adherence to the carotid can ultimately only be determined at surgery during subadventitial dissection.

The ***Shamblin classification*** (Figure 10) groups carotid body tumours according to the degree of encasement of the carotid vessels. *Group I* tumours are minimally attached to the carotids and are easily resected. *Group II* tumours partially surround the carotids, are generally more adherent to the adventitia and more difficult to resect, though still amenable to subadventitial resection. *Group III* tumours encase the entire circumference at the carotid bifurcation; surgical dissection may be impossible and is more likely to require sacrifice and grafting of the internal carotid. As stated above, nonsurgical treatment *e.g.* radiation



therapy should be considered for Group III tumours; if surgery is elected, it may be prudent to do an angiogram to check cerebral crossflow, and the surgeon should be experienced, and a vascular surgeon should be on standby.



*Figure 10: Shamblin classification of carotid body tumours; all 3 tumours on the left were resected without vascular complications*

### ***Surgical relationship to carotid vessels***

CT or MRI is employed to determine the position of the internal and external carotid arteries relative to the mass to provide a roadmap for the surgeon to plan a surgical approach.

### ***Multiple paragangliomas***

Additional paragangliomas may influence management and should be suspected in patients with a family history, and with head and neck paragangliomas that have raised catecholamines. They may be detected by imaging studies *e.g.* ultrasound, CT,

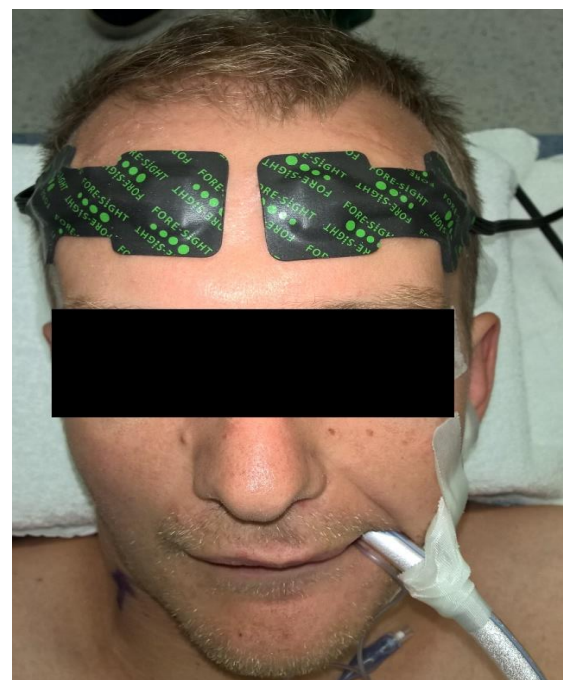MRI or angiography. A somatostatin receptor scan (octreotide scan) can also be very useful to assess the entire body to detect multiple paragangliomas.

### ***Principal feeding vessel(s)***

The ascending pharyngeal artery is generally the principal feeding vessel for carotid body tumours. Some surgeons prefer to have the artery embolised preoperatively to facilitate the resection.

### ***Stroke risk with occlusion of common or internal carotid artery***

When concerns exist that cerebral blood flow may be interrupted when resection necessitates division of the common or internal carotid arteries, then preoperative angiography (with balloon occlusion test to check for patency of the Circle of Willis) may be employed to check the degree of cerebral crossflow. When available, it is recommended to use perioperative brain oxygen saturation monitoring (*Figure 11*).



*Figure 11a: Electrodes placed on patient's forehead to monitoring brain oxygenation using the ForeSight system ®*

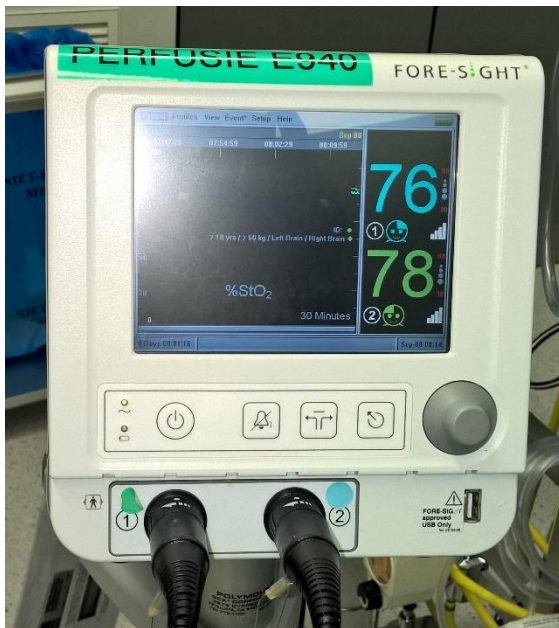

Figure 11b: Symmetry of oxygenation can be followed throughout the procedure using the ForeSight system ®

### Clinical presentation

- Cervical mass
  - Generally, a non-tender asymptomatic mass; vagal paragangliomas may be more cephalad
  - Mobile in transverse, but not vertical planes
  - May be pulsatile and have a bruit
  - May extend cephalad within the poststyloid parapharyngeal space to the cranial base and medially displace the lateral pharyngeal wall
  - May produce vague pain, hearing loss, pulsatile tinnitus
- Bilateral (10% carotid body tumours)
- Nerve palsies in about 10%
  - Cranial nerves IX (velopharyngeal insufficiency), X (hoarseness, aspiration), XI (shoulder weakness), XII)
  - Horner's syndrome
- Pheochromocytoma-like symptoms: up to 3% secrete catecholamines

### Preoperative assessment

- Is it a paraganglioma?
  - Family history
  - MEN type 2A and 2B
  - Imaging (do not required all three)
    - CT with contrast
    - MRI
    - Angiography
- Is it secreting or non-secreting?
  - 24-hour urinary catecholamines and metanephrines
  - Plasma metanephrine if at high risk *e.g.* predisposing genetic syndromes, family history of pheochromocytoma)
- If secreting
  - Exclude pheochromocytoma
  - Refer to physician or anaesthetist for pre- and perioperative optimisation including adrenergic receptor blocking agents
- Has a “Wait and scan” strategy demonstrated growth?
- Is it resectable – what is the Shamblin group?
- Is it malignant?
- Is the patient a good surgical candidate?
- What alternative management is available?
- Are there other paragangliomas?
  - Ultrasound neck and abdomen
  - CT / MRI of skull base to abdomen
  - MIBG scan
- If for surgery
  - Possible consequences and complications?
  - What side to operate on 1<sup>st</sup> with bilateral carotid body tumours?
    - Generally, operate on easier side as less likely to cause cranial nerve complications
    - If have cranial nerve complication, then still have the option to observe or irradiate the 2<sup>nd</sup> side



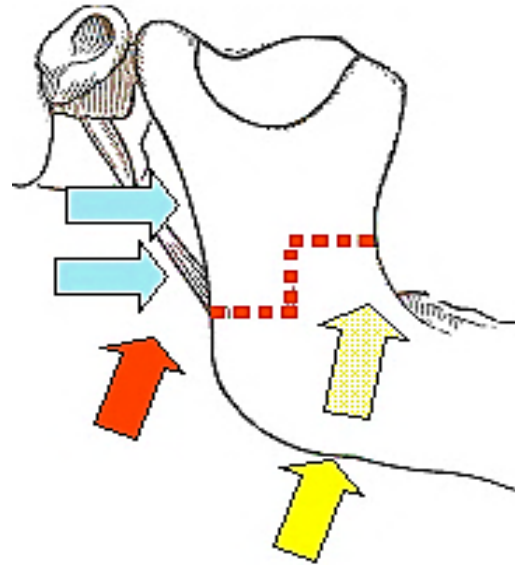
- What is the position of the carotid vessels relative to the tumour?
  - Important for planning the surgical approach and performing the surgery
  - Contrast CT / MRI / angiogram
- Should the tumour be embolised preoperatively?
  - Conflicting views among surgeons about benefits of embolisation
  - Potential for neurological complications
  - Greatest theoretical value with large tumours
  - Most commonly embolise the ascending pharyngeal artery
- What is the cerebral crossover blood flow like should the common or internal carotid artery have to be sacrificed? Should this be a concern it can be determined by angiography +/- balloon occlusion tests

### Surgical approaches

The principal challenges relating to post-styloid masses are avoiding injury to the internal carotid artery, internal jugular vein and the lower cranial (especially XII) and sympathetic nerves. Access is limited by the vertical ramus of the mandible, the parotid gland, the facial nerve and the styloid process with its muscular and ligamentous attachments.

Carotid and vagal paragangliomas are located in the poststyloid parapharyngeal space and are initially approached via the transcervical approach; additional anterior exposure is achieved by a transcervical-submandibular approach; and additional superior access is achieved by including the transparotid approach (*Figures 12, 22*). (See chapter [Access to Parapharyngeal Space](#)). Patients should therefore always be consented for transcervical and transparo-

tid approaches. The authors have never had to resort to a mandibulotomy.



*Figure 12: Surgical approaches: transcervical submandibular (yellow), transparotid (blue), and transcervical ± mandibulotomy (red)*

### Consent

Patients should be cautioned about the sequelae of vascular and lower cranial nerve injury, as well as injury to the sympathetic trunk causing Horner's and "1<sup>st</sup> Bite" syndromes.

### Anaesthesia

- Oral or nasal endotracheal intubation
- Avoid muscle relaxants so that cranial nerves VII, X, XI, XII can be monitored
- No antibiotics unless pharynx is entered
- Routine anaesthetic monitoring unless a secreting paraganglioma
- If a secreting tumour
  - Ensure that adrenergic system was adequately blocked in the preoperative phase
  - Monitor blood pressure with arterial line

- Have appropriate drugs available to control blood pressure fluctuations
- Blood: either Grouped and Screened, or cross matched
- Brain oxygenation can be monitored particularly with Shamblin 3 tumour resections (*Figures 12 a, b*)

### **Surgical equipment to have available**

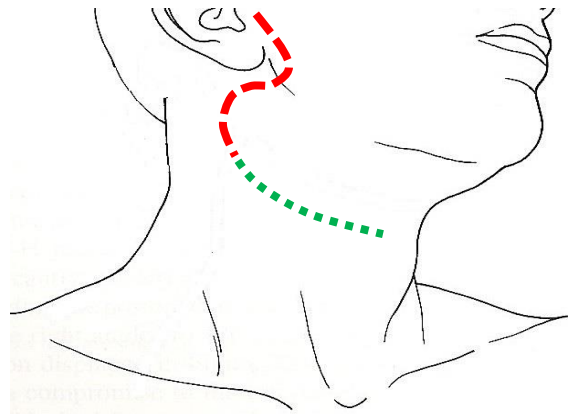
- Bipolar electrocautery
- Vascular sutures and vascular loops to place around vessels and nerves
- Vascular forceps
- Lahey vascular clamp (*Figure 13*)



*Figure 13: Lahey vascular clamp*

### **Surgical technique**

- Place the patient supine with neck extended and turned to the opposite side
- Inject local anaesthetic with 1/100000 adrenaline along the incision line, especially preauricularly
- Sterilise the face and neck
- Drape the patient but keep the corners of the mouth and eye exposed to monitor facial movement if a transparotid approach is to be employed
- Open the neck as indicated in *Figure 14*. The incision for the transcervical approach is made at the level of the hyoid bone. The parotid incision may be delayed until it is found that the transcervical approach does not provide adequate access

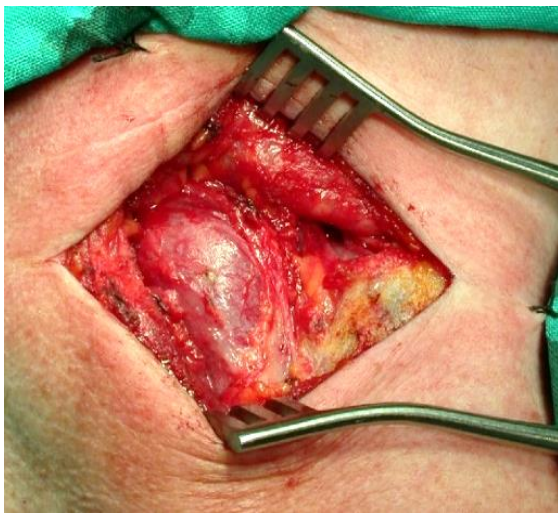


*Figure 14: Skin incisions: Green for transcervical +/- submandibular approach; add red incision for transparotid approach*

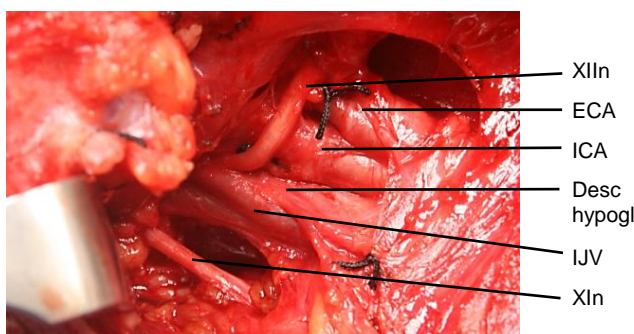
### **Transcervical approach (*Figure 15*)**

- The transcervical approach is suited to paragangliomas extending up to the level of the styloid process
- Expose the upper neck via a transverse skin crease incision at the level of the hyoid bone (*Figure 14*)
- Extend the skin incision posteriorly over the sternocleidomastoid muscle
- Divide the platysma muscle taking care not to injure the greater auricular nerve which should be preserved
- Ligate and divide the external jugular vein just anterior to the greater auricular nerve to improve access to the upper neck
- Identify the paraganglioma, taking care not to traumatise its thin-walled surface vessels (*Figure 15*)
- Proceed to identify as many of the following anatomic structures around the paraganglioma (*Figure 16*)
  - Common carotid artery
  - Carotid bifurcation
  - Internal carotid artery
  - External carotid artery
  - Internal jugular vein
  - Posterior belly of digastric muscle
  - Hypoglossal nerve
  - Descendens hypoglossi
  - Vagus nerve
  - Accessory nerve

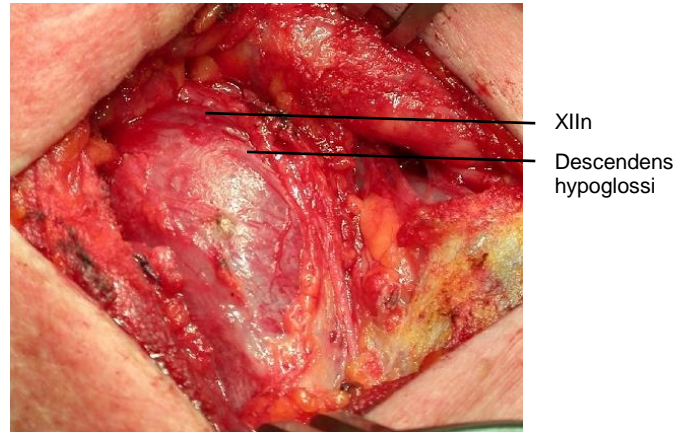
- Sympathetic trunk
- Superior laryngeal nerve
- One may opt to place vascular loops around the major vessels for vascular control should a vascular injury occur (*Figure 6*)
- Use a combination of sharp dissection and bipolar cautery to dissect nerves free that are trapped in the surface of the mass, most commonly the hypoglossal nerve (*Figure 17*)



*Figure 15: Carotid body tumour exposed in right neck*

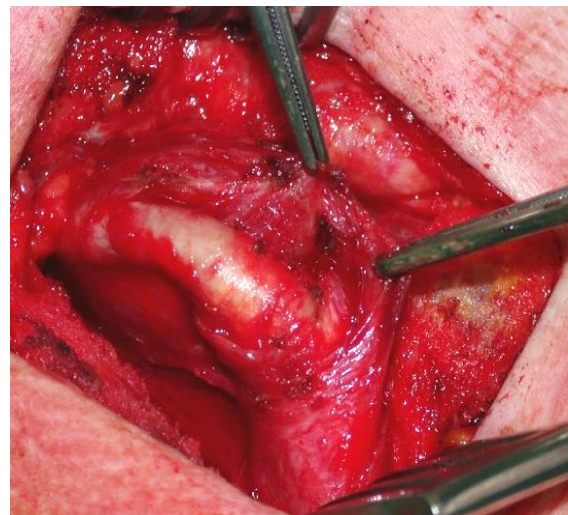


*Figure 16: Structures around a paraganglioma; the sympathetic trunk is found on the posterior aspect of the carotid sheath*



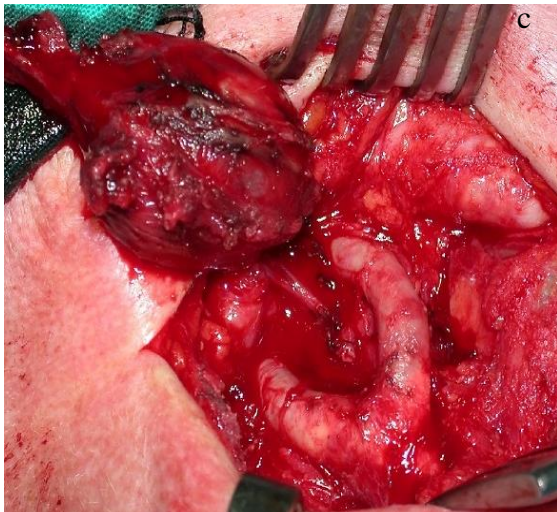
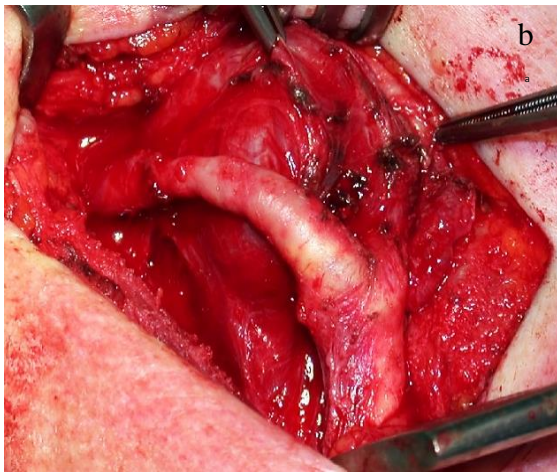
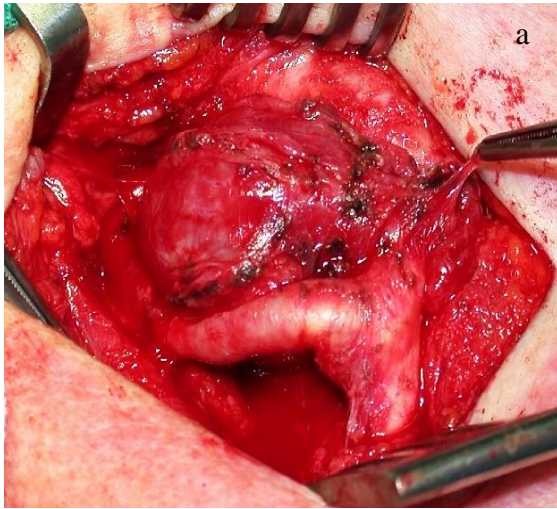
*Figure 17: XIIIn and descendens hypoglossi running in the surface of the paraganglioma, having to be dissected free*

- Next direct your attention to the periphery of the mass at the common, internal or external carotid arteries or the carotid bifurcation
- Establish a subadventitial dissection plane on the artery (*Figure 18*)
- Dissect the mass off the arteries with scissors keeping in this subadventitial plane (*Figures 18, 19, 20*)

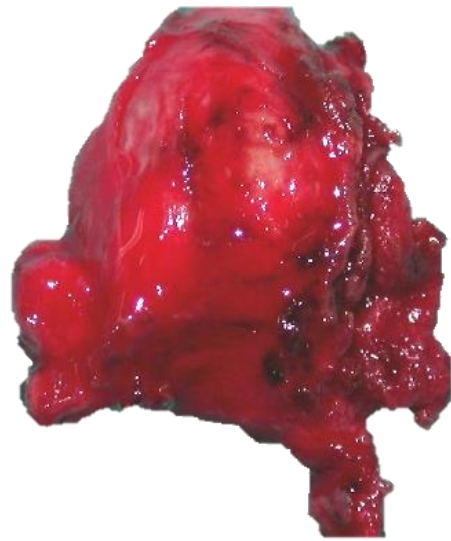

*Figure 18: Freeing the paraganglioma from the internal carotid artery in a subadventitial dissection plane*





*Figures 19a, b, c: Freeing the paraganglioma from the carotid bifurcation and external carotid artery in a subadventitial plane*



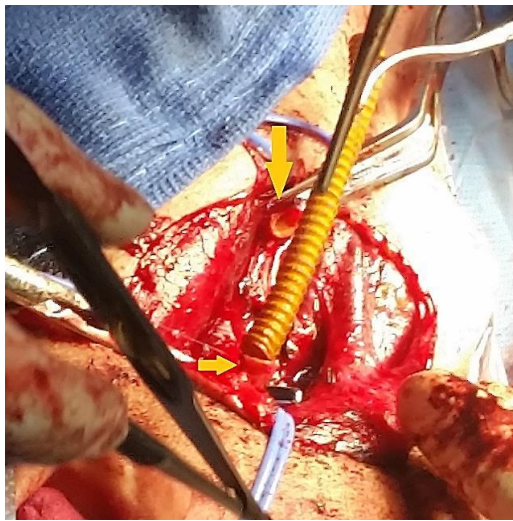*Figure 20: Resected carotid body tumour*

#### *Surgical tips*

- Identify and preserve the nerves listed above during the course of the dissection
- Maintain a dry surgical field at all times by using bipolar cautery and ties for haemostasis
- Avoid excessive cautery on the carotid wall as this may weaken the artery and cause it to rupture; also, in the post-operative phase a pseudoaneurysm may form and only rupture days later
- Avoid excessive manipulation or rotation of the carotid vessels as this may cause thrombosis or release plaque or emboli causing a stroke
- Be very careful not to injure the arterial wall when dissecting within the carotid bifurcation
- The surgeon may elect to divide and ligate or oversew (with proline) the external carotid artery and to resect external carotid artery with the tumour; avoid dividing the artery close to the bifurcation as it is more difficult to ligate the artery at this point, there may be plaque at the bifurcation, and the artery may tear if ligated too close to the bifurcation



- Be prepared to have to repair the carotid vessels if traumatised, so have vascular sutures, vascular forceps and a Lahey vascular clamp available in the operating room (*Figure 21*). Depending on your own experience it may be prudent to have your vascular surgical colleague on standby



*Figure 21: After subadventitial dissection the remaining carotid wall was too thin and the risk of subsequent aneurysmic blow-out was judged too high; hence the common carotid (vertical arrow) to internal carotid (horizontal arrow) was replaced with a Dacron ® interposition graft and the external carotid was ligated. During this procedure the ForeSight system ® provided information of the patency of the circle of Willis and brain oxygenation. The patient did well postoperatively*

#### **Gaining additional exposure (*Figure 12*)**

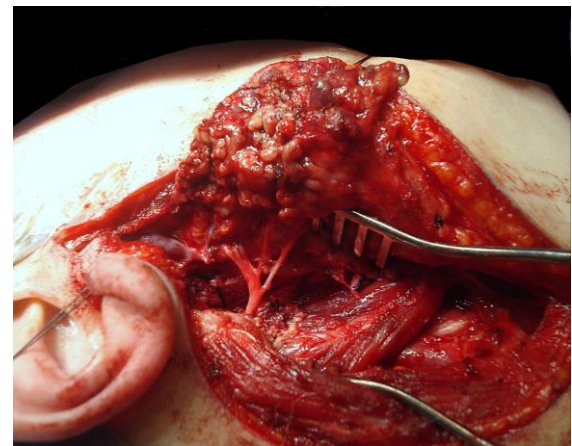
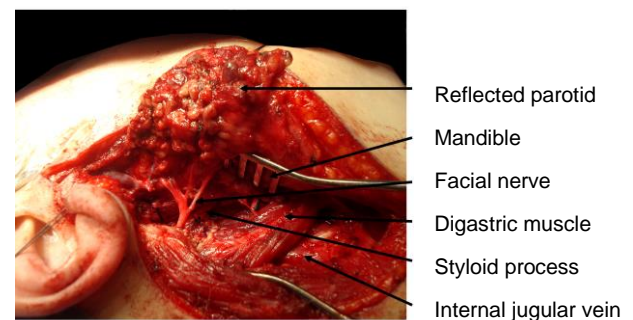
Additional exposure may be achieved by adding one or more of the following approaches to the transcervical approach:

- Transecting posterior belly of digastric muscle
- Transparotid approach
- Transcervical-submandibular approach
- Mandibulotomy of vertical ramus

#### ***Transecting posterior belly of digastric***

- The posterior belly of the digastric muscle may either be retracted superiorly or divided to provide additional access medial to the parotid gland and the facial nerve
- Take care not to injure the facial nerve as it bifurcates the angle between the styloid process and the digastric muscle

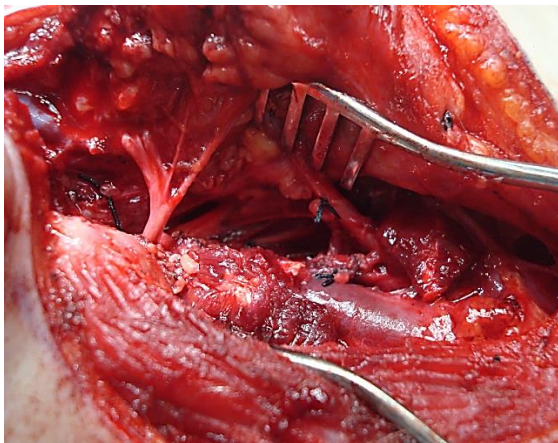
#### ***Transparotid approach***



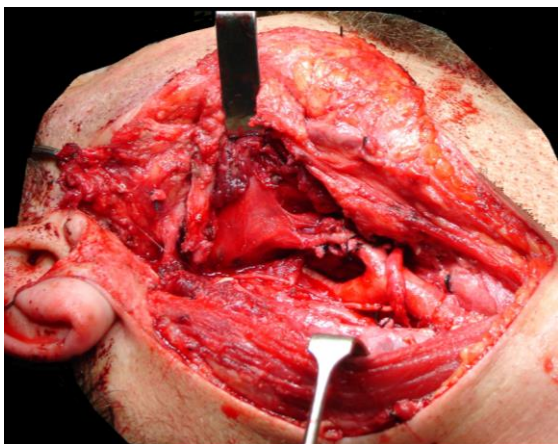
*Figures 22a, b: Transparotid access*

- Elevate the superficial lobe of the parotid gland off the trunk of the facial nerve up to the *pes anserinus* and retract the gland anteriorly (*Figure 22*)
- Free the facial nerve from the deep lobe of the parotid gland
- Excise the deep parotid lobe in the retromandibular sulcus (*Figure 22*)
- This exposes the styloid process

- Immediately deep to the styloid are the contents of the poststyloid PPS including the internal carotid artery
- Access can be further improved by excising the styloid process with a bone nibbler, dividing the stylomandibular ligament, and retracting the mandible anteriorly (taking care to avoid excessive tension on the facial nerve), and inferiorly by dividing the posterior belly of the digastric and “styloid muscles” (Figures 23, 24)



*Figure 23: Additional access by transecting digastric muscle and styloid apparatus*

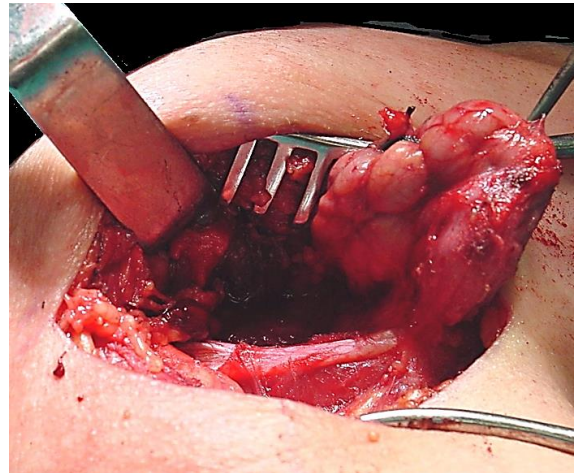


*Figure 24: Wide access to PPS following resection of large glomus vagale tumour*

#### ***Transcervical submandibular approach (Figure 25)***

Tumours extending anteriorly may require combinations of transparotid, transcervical

and transcervical submandibular approaches. Transecting the posterior belly of the digastric muscle and/or the “styloid muscles” further improves access.



*Figure 25: Additional access by dividing the facial artery where it appears above digastric, and displacing submandibular gland anteriorly*

#### **Closure**

- Insert a closed suction drain
- Close the skin in a normal fashion

#### **Postoperative care**

- Remove suction drains when <50ml drainage / 24 hrs
- Check that patient swallows without aspirating before introducing oral feeding

#### **Complications**

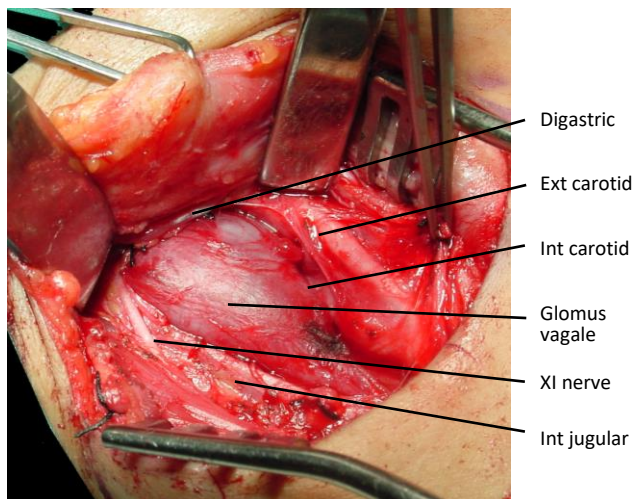
- Haematoma
- Cranial nerve injuries VII, IX, X, XI, XII
- Sympathetic trunk injury
  - First bite syndrome
  - Horner's syndrome
- Cerebrovascular accident
- Carotid artery injury causing false aneurysm or blowout



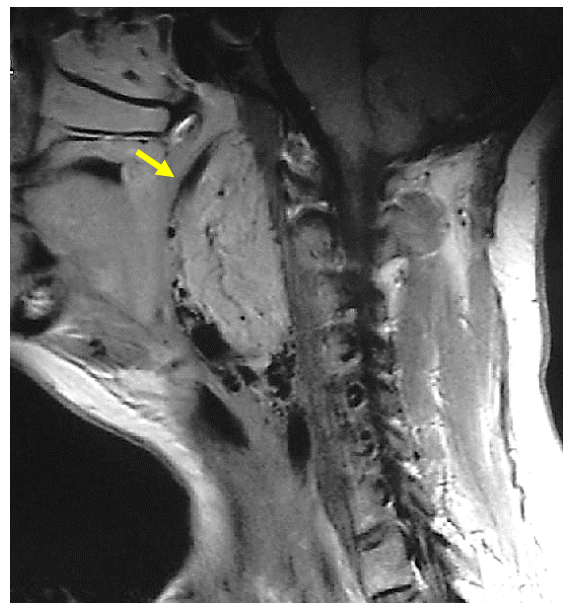
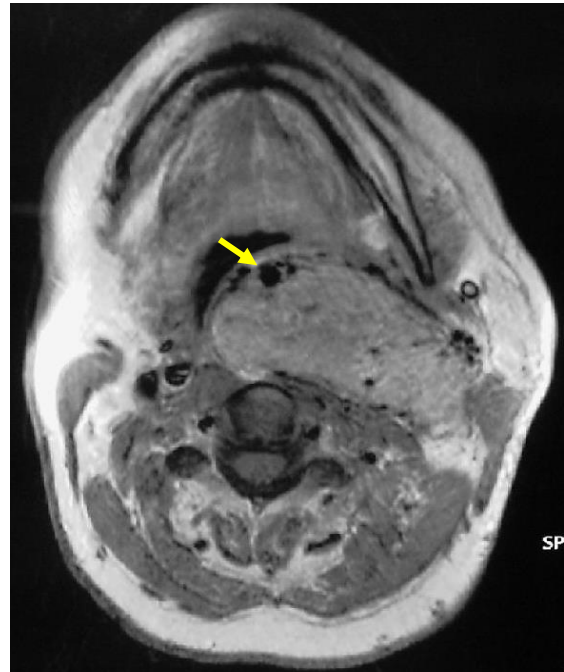
## Glomus vagale / vagal paraganglioma

Unlike carotid body tumours, glomus vagale tumours generally displace the carotid vessels anteriorly (*Figures 26, 27, 28*). They may extend through the skull base as a dumbbell tumour. Therefore, imaging to demonstrate the anatomical relationship of the internal carotid artery to the mass is essential to permit surgical planning and to safely perform the surgery.

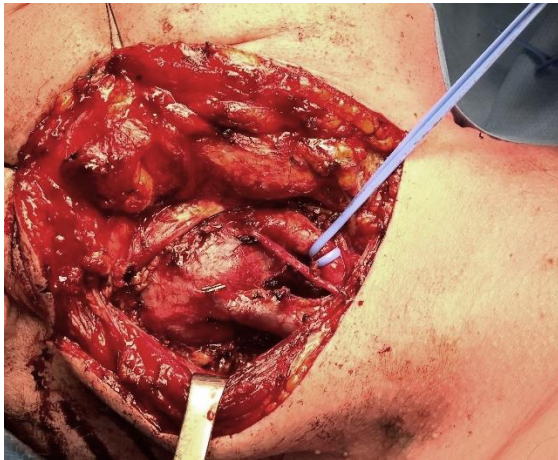
Because the vagus nerve is generally sacrificed with the resection (*Figure 28d*), some patients may elect to adopt a watchful waiting approach to preserve voice function for as long as possible.



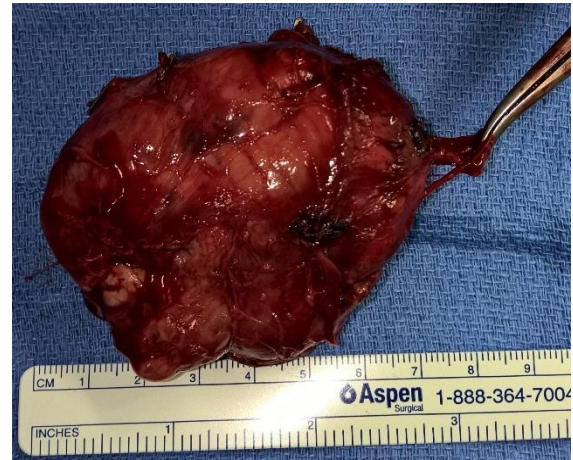*Figure 26: Glomus vagale tumour located between the internal jugular vein and the internal carotid artery*



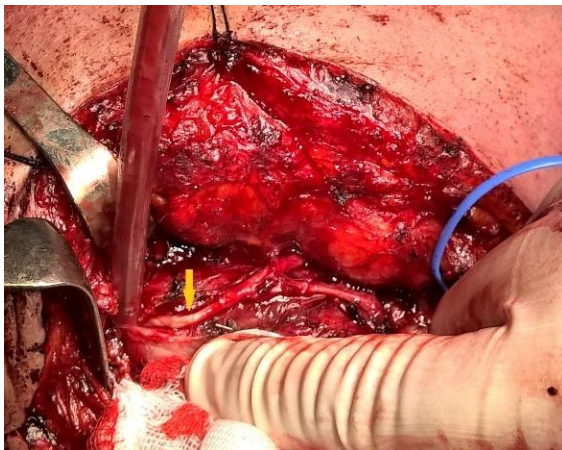
*Figures 27a, b: Glomus vagale tumour displacing the internal carotid artery (yellow arrow) anteriorly*



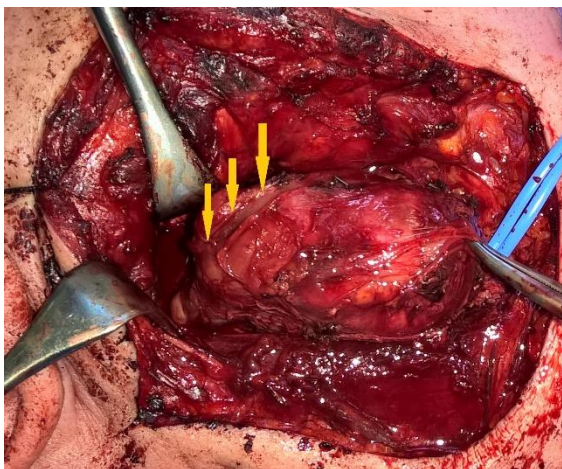
*Figure 28a: Secreting glomus vagale tumour between carotid artery and jugular vein; descendens hypoglossi nerve visible*



*Figure 28d: Resected specimen of secreting glomus vagale tumour with the clamp holding the transected vagus nerve*



*Figure 28b: Dissecting the XIIIn out of glomus vagale tumour capsule*



*Figure 28c: Glomus vagale tumour being removed; note groove from which XII nerve was dissected (arrows)*

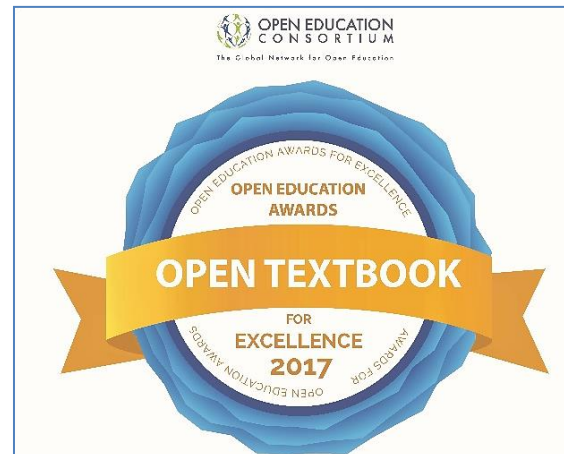
## References

1. Mendenhall WM, Amdur RJ, Vaysberg M, Mendenhall CM, Werning JW. Head and neck paragangliomas. *Head Neck* 2011;33:1530-4
2. van der Mey AG, Frijns JH, Cornelisse CJ et al. Does intervention improve the natural course of glomus tumors? A series of 108 patients seen in a 32-year period. *Ann Otol Rhinol Laryngol* 1992;101:635-42
3. Langerman A, Athavale SM, Rangarajan SV, Sinard RJ, Nettekville JL. Natural history of cervical paragangliomas: outcomes of observation of 43 patients. *Arch Otolaryngol Head Neck Surg.* 2012 Apr;138(4):341-5
4. Foote RL, Pollock BE, Gorman DA et al. Glomus jugulare tumor: tumor control and complications after stereotactic radiosurgery. *Head Neck* 2002;24:332-8
5. Verniers DA, Keus RB, Schouwenburg PF, Bartelink H. Radiation therapy, an important mode of treatment for head and neck chemodectomas. *Eur J Cancer* 1992;28A:1028-1033
6. Suarez C, Rodrigo JP, Bodeker CC et al. Jugular and vagal paragangliomas: Systematic study of management with



surgery and radiotherapy. *Head Neck* 2013 Aug;35(8):1195-204

7. Suarez C, Rodrigo JP, Mendenhall WM et al. Carotid body paragangliomas: a systematic study on management with surgery and radiotherapy. *Eur Arch Otorhinolaryngol* 2014 Jan;271(1):23-34
8. Martin TP, Irving RM, Maher ER. The genetics of paragangliomas: a review. *Clin Otolaryngol* 2007;32:7-11



### Author & Editor

Johan Fagan MBChB, FCS (ORL), MMed  
Professor and Chairman  
Division of Otolaryngology  
University of Cape Town  
Cape Town, South Africa  
[johannes.fagan@uct.ac.za](mailto:johannes.fagan@uct.ac.za)

### Author

Vincent Vander Poorten MD PhD MSc  
Professor  
Otorhinolaryngology, Head & Neck  
Surgery  
University Hospitals Leuven  
Department of Head and Neck Oncology  
KU Leuven, Belgium  
[vincent.vanderpoorten@uzleuven.be](mailto:vincent.vanderpoorten@uzleuven.be)

### **THE OPEN ACCESS ATLAS OF OTOLARYNGOLOGY, HEAD & NECK OPERATIVE SURGERY**

[www.entdev.uct.ac.za](http://www.entdev.uct.ac.za)



The Open Access Atlas of Otolaryngology, Head & Neck Operative Surgery by [Johan Fagan \(Editor\)](mailto:johannes.fagan@uct.ac.za) [johannes.fagan@uct.ac.za](mailto:johannes.fagan@uct.ac.za) is licensed under a [Creative Commons Attribution - Non-Commercial 3.0 Unported License](https://creativecommons.org/licenses/by-nc/3.0/)