

ANALYSIS OF INTRA OPERATIVE TRAUMA OF SLIM MODIOLAR ELECTRODE

LABAEYE Solange¹, DAOUDI Hannah^{1,3}, LAHLOU Ghizlene^{2,3}, MOSNIER Isabelle^{2,3}, NGUYEN Yann^{2,3}, FERRARY Evelyne^{2,3}, MAMELLE Elisabeth^{1,3}, TORRES Renato^{2,3}

1 APHP, Sorbonne Université, Hôpital Rothschild, Service d'ORL et de Chirurgie Cervico-faciale, Paris, France; 2 APHP, Sorbonne Université, GHU Pitié-Salpêtrière, Service d'ORL et de Chirurgie Cervico-faciale, UF Implants Auditifs, F-75013, Paris, France. 3 Université Paris Cité, Institut Pasteur, AP-HP, Inserm, Fondation Pour l'Audition, Institut de l'Audition, IHU reConnect, F-75012 Paris, France

INTRODUCTION

The CI632 is a perimodiolar electrode array (Cochlear AG, Lane Cove, Australia). Thinner perimodiolar electrode array on the market (Thickness = 0.35 mm apical and 0.475 mm basal).



Does the characteristics of the CI632 electrode lead to a reduction of intracochlear trauma?

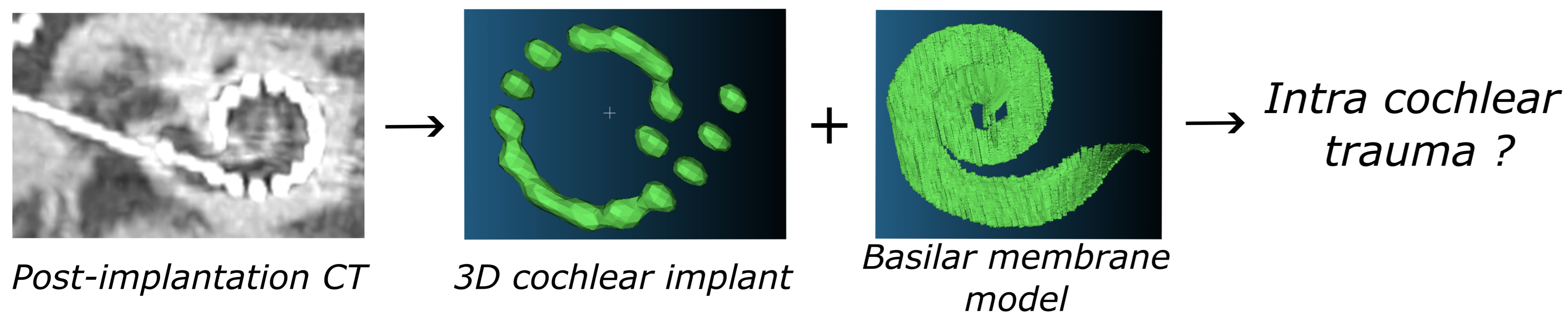
METHODS

23 patients from two reference centers (Pitié Salpêtrière and Rothschild hospitals) were included from July 2021 to December 2023

--> 4 bilaterally implanted patients --> 27 cochlear implantations

Post-implantation evaluation:

Intracochlear trauma: 3D reconstruction



Auditory outcomes at 1 year post-implantation:

- Speech performance in quiet : dyssyllabic words (Fournier list)
- Speech performance in noise : MBAA words at 10dB SNR

RESULTS

27 cochlear implantations

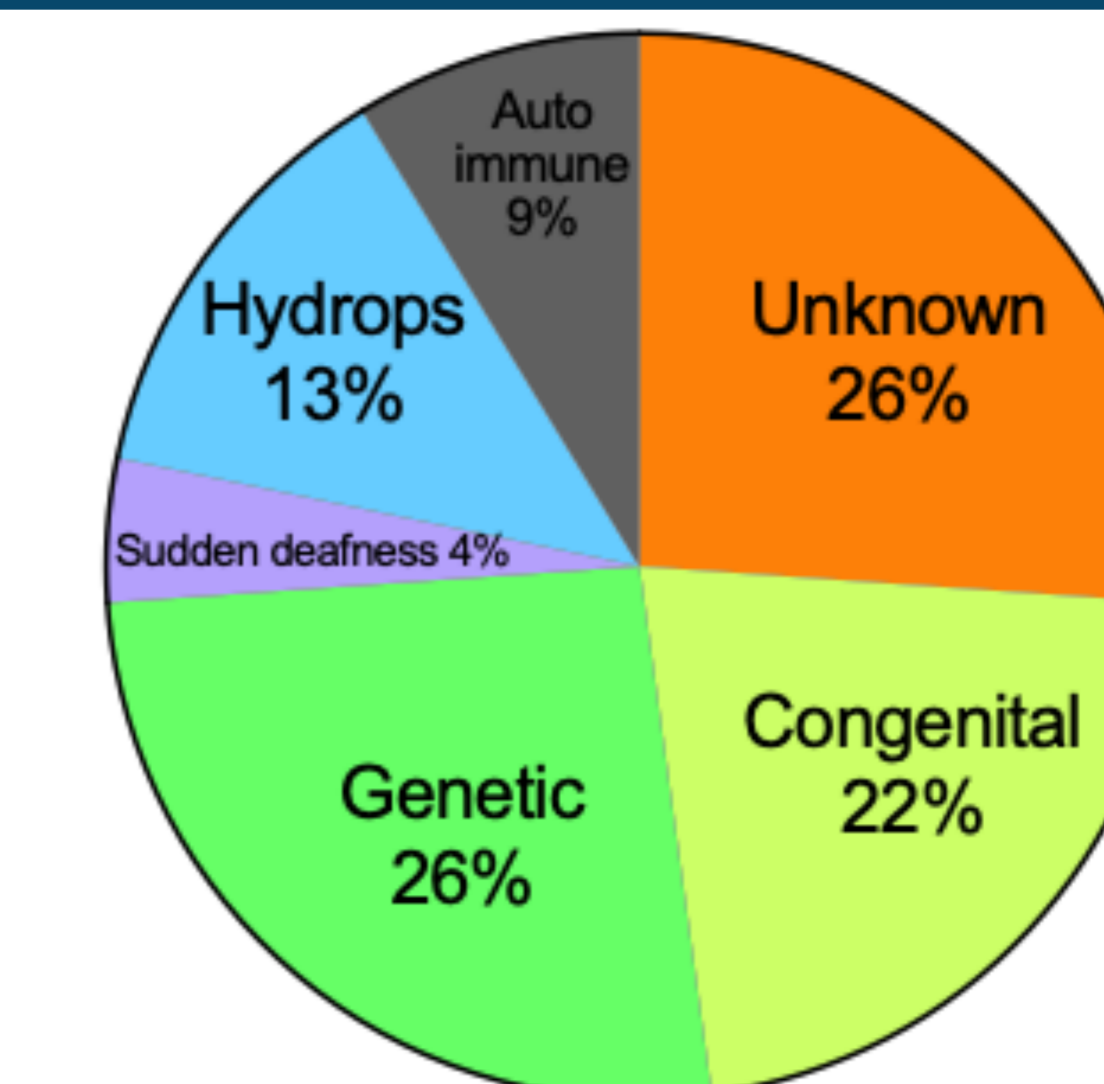
Duration of profound hearing loss: 15 ± 12 years [1–50]

Mean age at implantation: 51 ± 15 years [21–82]

Pre-implantation hearing:

PTA: 110 ± 12 dB [80–120]

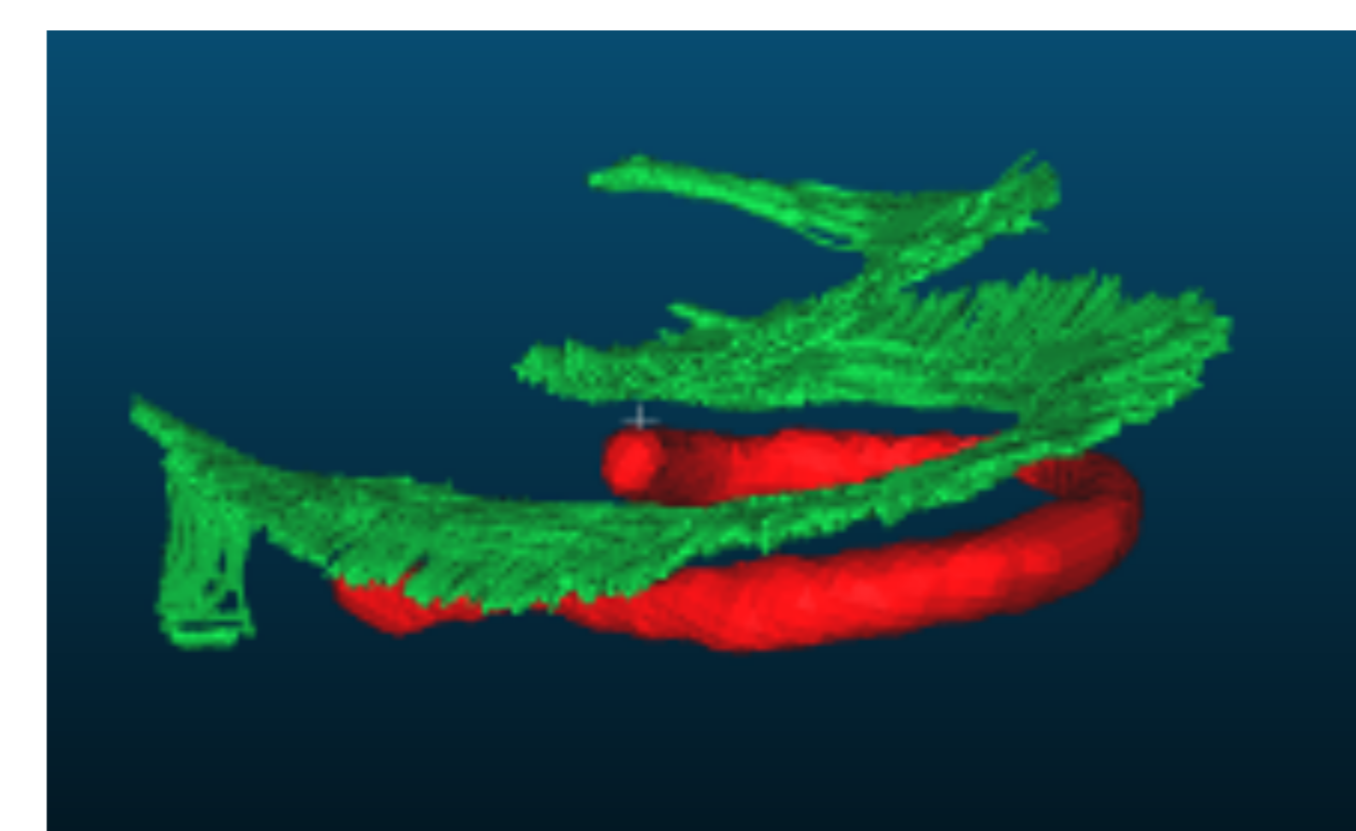
Speech intelligibility in quiet at 60 dB: $5 \pm 12\%$ [0–44]



Etiologies

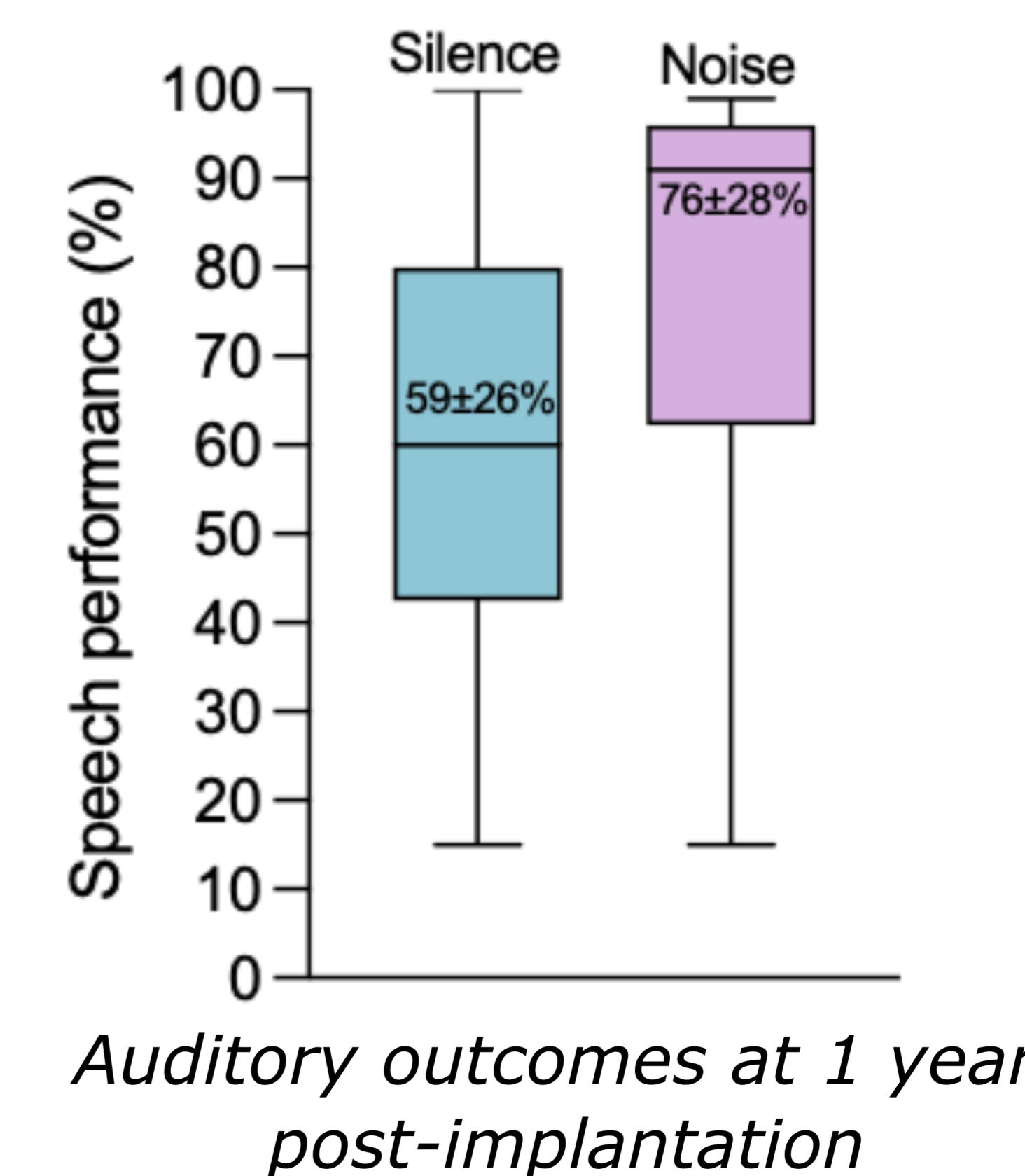
26/27 cochlear insertions let to no intracochlear trauma (96%)

Mean insertion depth : $385 \pm 39^\circ$ [303–445]




● Electrode array ● Basilar membrane

3D reconstruction showing an complete scala tympani insertion



One insertion led to intracochlear trauma



Insertion depth: 430°

Translocation of 11/21 electrodes

Good auditory outcomes at 1 year post-implantation:

Speech intelligibility in silence: 90%

Speech intelligibility in noise: 98%

CONCLUSION

This study showed a quasi-atraumatic insertion in patients who underwent CI632 electrode array insertion, probably due to a low insertion depth. Despite not covering all frequencies in accordance with cochlear tonotopy, the Slim Perimodiolar electrode still facilitated good auditory performance in both quiet and noisy conditions.

Funding and acknowledgement: The authors thank *Fondation Pour l'Audition* (FPA CRA02 and Starting Grant 2020 Yann Nguyen FPA IDA08, FPA-WCA Travel grant 2024 Hannah Daoudi). This work has benefited from a French government grant managed by the Agence Nationale de la Recherche under the France 2030 program, reference ANR-23-IAHU-0003.